

# The use of SPECT to evaluate growth cessation of the mandible in unilateral condylar hyperplasia

**P. Pripatnanont<sup>1</sup>,  
P. Vittayakittipong<sup>1</sup>, U. Markmanee<sup>2</sup>,  
S. Thongmak<sup>2</sup>, T. Yipintsoi<sup>2</sup>**

<sup>1</sup>Department of Oral and Maxillofacial Surgery, Faculty of Dentistry, Prince of Songkla University, Thailand; <sup>2</sup>Division of Nuclear Medicine, Department of Radiology, Faculty of Medicine, Prince of Songkla University, Hatyai, Songkhla, 90112, Thailand

*P. Pripatnanont, P. Vittayakittipong, U. Markmanee, S. Thongmak, T. Yipintsoi: The use of SPECT to evaluate growth cessation of the mandible in unilateral condylar hyperplasia. Int. J. Oral Maxillofac. Surg. 2005; 34: 364–368. © 2004 International Association of Oral and Maxillofacial Surgeons. Published by Elsevier Ltd. All rights reserved.*

**Abstract.** In unilateral condylar hyperplasia, for surgical intervention to be effective, the status of condylar bone growth has to be assessed correctly. Previously this assessment relied on serial clinical observations. This study aimed to evaluate the MDP-SPECT method of assessing condylar growth in unilateral condylar hyperplasia. Twenty-six MDP-SPECT of the mandible had been performed; 21 were diagnosed as condylar hyperplasia and five as non-mandibular disease. Three isotope parameters: isotope counts, pixel counts and counts per pixel were summed for each condyle per subject. The percentage difference in isotope uptake of the three parameters between the two condyles was calculated as the ratio of the combined counts of the two sides. These differences significantly correlated with each other (Pearson  $r = 0.78-0.98$ ) and with the clinical status of bone growth (Spearman  $\rho = 0.72-0.86$ ). There was a significant difference for the count per pixel between the 'growing' condyle (transaxial, T:  $15.05 \pm 7.14$ , coronal, C:  $12.29 \pm 7.88$ ), the 'no further growth' condyle (T:  $5.22 \pm 4.08$ , C:  $5.67 \pm 3.88$ ) and the 'normal' condyle (T:  $0.82 \pm 0.76$ , C:  $1.34 \pm 0.66$ ). This method was able to separate 'active growth' from 'growth cessation' of the condyle by a single MDP-SPECT of the mandible. However, further studies are needed to confirm this finding.

**Key words:** bone scan; condylar hyperplasia; MDP; scintigraphy; SPECT.

Accepted for publication 4 November 2004  
Available online 26 January 2005

Mandibular condylar hyperplasia is a complex deformity of the condyle and the mandible that leads to facial asymmetry. Based on clinical, radiographic and histological findings, OBWEGESER & MAKEK<sup>12</sup> described two types: hemimandibular hyperplasia (HH) and hemimandibular elongation (HE). Hemimandibular hyper-

plasia is characterized by a three-dimensional enlargement of one side of the mandible terminating exactly at the symphysis of the affected side. It usually presents in childhood. Histologically, a very broad layer of fibrocartilage covers the condyle homogeneously. HE is a horizontal displacement of the mandible towards the

unaffected side, and the horizontal rami of both sides lie on the same level. Unlike HH, it usually occurs in the older patient and the pathological hyperactive growth occurs in the center of the condyle.

The therapeutic principle is primarily surgical with or without orthodontics, and depends on the age of the patient, degree

of severity and the status of condylar growth<sup>11,12</sup>. A corrective osteotomy performed after cessation of bone growth is likely to be stable; otherwise there is a potential for the deformity to recur. In cases of persistent growth associated with progressive facial asymmetry, interceptive surgery to remove the hyperplastic condyle by high condylectomy may help to limit the deformity<sup>1,7,8,17</sup>. Therefore, condylar growth assessment is crucial for the timing of surgery.

Using clinical modalities to determine the cessation of mandibular growth is not accurate and needs at least two measurements 6–12 months apart, which may cause unnecessary delay, particularly in children in whom sub-total condylectomy is indicated. Planar scintigraphy with 99m Tc-MDP (technetium methylene diphosphonate) has been used to assess growth activity of the condyle<sup>4,6,10,13,17</sup>, but lacked anatomical precision. MDP-SPECT (single photon emission computer tomography) has the capability of 3D reconstruction and subsequent thin sectioning; however, there are at present no discriminating features of MDP-SPECT for assessing condylar growth except for the report of HODDER et al. which relied on surgical outcome as the gold standard<sup>3,8,14</sup>.

The first aim of the current study was to test whether MDP-SPECT can be used to determine the status of condylar growth in unilateral condylar hyperplasia. The second aim was to evaluate the accuracy of three isotope uptake parameters (isotope count, pixel count and count per pixel) of the condyle by using the contralateral side as the reference point and comparing each measurement to the clinical progress. It is hypothesized that the differences in SPECT isotope uptake between the abnormal and normal condyle can be a predictive indicator of growing condyles.

## Patients and methods

### Study design and sample

This study was a prospective clinical trial of patients presenting with unilateral condylar hyperplasia from 1998 to 2003. The study was approved by the Ethics Committee of the Faculty of Dentistry, Prince of Songkla University. The inclusion criteria were patients aged 12–45 years with either HH or HE and no orthodontic treatment, available for follow up and clinical examination every 6 months for at least 1 year, and consenting to undergo MDP-SPECT examination. Exclusion criteria were patients with recent history of trauma

to the temporomandibular joint (TMJ), TMJ disease or history of tooth extraction in the past 6 months.

Patients who had undergone an MDP bone scan for reasons not related to mandibular disease, and had clinically normal mandibles and TMJs, were asked to have an additional mandibular SPECT and were categorized as normal condyle patients.

### Diagnosis

All non-syndromic patients with mandibular asymmetry presenting during the study period were reviewed by an oral

and maxillofacial surgeon, who was not involved in the study, to confirm the diagnosis of either HH or HE, according to the criteria of OBWEGESER & MAKEK<sup>12</sup>, for inclusion in the study.

### Clinical examination

The clinical examination was performed on presentation as a baseline and then every 6 months as follows: Serial standard photographs (six) of the face to monitor the progression of facial asymmetry, serial dental casts to follow the change of dental midline, dental occlusion and open bite, orthopantomogram and serial lateral and postero-anterior cephalograms using the same X-ray machine and by a standardized technique.

### SPECT of the mandible

All patients had MDP-SPECT performed. 99m Tc-MDP (20 mCi) was given intravenously and the patient was scanned 3 h later with a Toshiba GCA-901A/AG. The rotation was 360° with a 30 s stop at 6° per view obtaining 30,000–50,000 counts at each stop. The matrix size was 128 × 128 and a low energy, high resolution (LEHR) parallel collimator was used. The peak energy was set at 140 keV with a 20% window width.

The image was pre-processed using a Butterworth filter with a cut-off frequency of 8 and 0.20, and back projected using a 'ramp' and Chang's attenuation. The reconstructed images in the transaxial (T) and coronal views (C) were then sliced with a thickness of 1 pixel. From selected slices, an ROI (region of interest) was

drawn around the structures considered to be the condyle by one investigator. The isotope and pixel counts for each ROI were determined and then summed to obtain the total isotope count (ic), total pixel count (pc) and total count per pixel (cpp) for each condyle.

The difference in isotope uptake (for each of the three parameters: total isotope count, total pixel count, total count per pixel) between the affected condyle and the contralateral (unaffected) condyle was expressed as a percentage of the combined counts of the two sides according to the following formula:

Percentage difference of isotope uptake (%Δ)

$$= \frac{[\text{uptake in the affected side} - \text{uptake in the unaffected side}]}{\text{total uptake of the affected and the unaffected sides}} \times 100$$

To validate the method of measurement, correlation between each parameter and the clinical result, and correlation between isotope uptake from the transaxial view and the coronal view, were calculated.

Five randomly selected cases were re-outlined for ROI and the above counts were measured twice by the same investigator to test intra-examiner reliability.

### Clinical assessments

For each subject, serial dental casts taken at intervals of 6 months were evaluated by three oral and maxillofacial surgeons, experienced in dentofacial deformity, who were neither involved in the project nor aware of the result of the bone scan. They independently scored 'change' (+1) or 'no change' (0) by examining dental occlusion, tooth and midline shift<sup>15</sup>. The final score was determined based on agreement of at least two surgeons.

Traced cephalograms were digitized using a software package (Dentofacial Planner Plus<sup>TM</sup> version 2.02 Patch, Toronto, Canada) to 0.1° and 0.1 mm. Distances and angles between landmarks were measured by one investigator and rated blindly by the other according to the research protocol. The lateral and PA views were evaluated separately. To enhance measurement reliability in the lateral cephalogram, both condylion (Co) and articulare (Ar) were used to measure mandibular length to gnathion (Gn) Co-Gn, Ar-Gn. Ramus height was measured from condylion to anatomic gonion (Go) Co-Go and from articulare to anatomic gonion (Ar-Go). Distance between sella (S) and gonion (S-Go), sella and gnathion

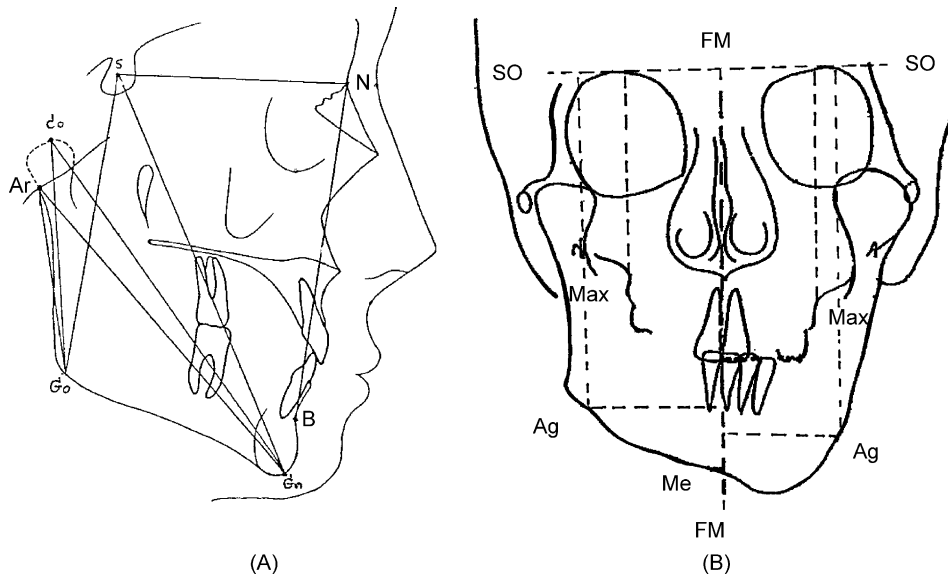


Fig. 1. (A) Bony landmark on lateral cephalogram and (B) bony landmark on PA cephalogram.

(S-Gn) and SNB were recorded<sup>9,16</sup> (Fig. 1A).

From the PA cephalogram, the following distances were measured to monitor the changes. Distance from crista galli to upper central incisor was used as the reference for reproducibility. Distance from maxillare to superior orbital plane (Max-SO) was used for evaluation of maxillary position in the vertical plane and canting of the maxilla. To localize the angle of the mandible in the vertical plane, the distance from antinion to superior orbital plane (Ag-SO) was used, and, in the horizontal plane, Ag to facial midline (Ag-FM) was used. Chin deviation was detected by the distance from menton (Me) to FM in the transverse plane<sup>9,16</sup> (Fig. 1B).

Normal variation (score = 0) was accepted if changes of less than 1 mm and 1° were seen in ≥3 parameters in the lateral cephalogram. The difference in magnification in the serial PA cephalogram was linearly corrected using the ratio of the normal halves at the two different time periods as the correction factor. Changes in PA cephalogram were considered insignificant if ≤3 parameters showed variation, and if the midline shift was less than 0.5 mm.

**Interpretation**

The scores from the dental casts, and lateral and PA cephalograms (each having a value of 0 or 1) were summed for each subject. The final clinical status of condylar growth for that subject was defined by a total score of three items

as follows:

Score 0–1 = no further growth

Score 2–3 = growing condyle

**Data analysis**

Intercooled Stata 7.0 for Windows was used to analyze data. To test intra-examiner reliability, the kappa statistic was used for the reliability of the ROI outline and Pearson correlation for the reliability of isotope uptake on the two occasions. To detect the correlation among the three parameters and the correlation of each parameter with clinical assessment, the Pearson correlation and Spearman Rho were used, respectively. To detect the differences among the three clinical groups (normal, no further growth, growing), the Kruskal–Wallis test and Mann–Whitney *U* test were used to compare the percentage differences of three isotope uptake parameters (%Δic, %Δpc, %Δcpp). An alpha level of 0.05 was accepted as statistically significant.

**Results**

**Clinical data**

Twenty-nine patients were entered into the study: five aged 19–56 years participated as the normal condyle group, seven were classified as hemimandibular hyperplasia (HH) and 17 as hemimandibular elongation (HE). One patient from the HH group and two from the HE group were lost to follow up and were excluded from the study. Condylar growth, using clinical criteria, was considered ‘growing’ in four HH and eight HE and ‘no further growth’ in two HH and seven HE (Table 1).

**SPECT data**

*Intra-examiner reliability*

The repeat measurement of five randomly selected cases showed good intra-examiner reliability in identification of the ROI: kappa statistic of ROI was 0.74 for the combined transaxial and coronal view (0.6–0.8 = substantial agreement), 0.70

Table 1. Demographic data and clinical status of condylar growth

Characteristics	Normal	Hemimandibular hyperplasia (HH)	Hemimandibular elongation (HE)
Age (year)	19–56	12–26	14–46
Sex			
Male	2	4	3
Female	3	2	12
Clinical status			
No further growth	5	2	7
Growing (follow up time, year)	–	4 (1–2.5)	8 (1–4)
Total number	5	6	15

Table 2. Percentage difference of various isotopic activity of the condyle grouped according to the clinical status, diagnosis and SPECT views

Clinical status	Diagnosis	SPECT percent difference of isotopic count (% $\Delta$ ic)		SPECT percent difference of pixel count (% $\Delta$ pc)		SPECT percent difference of count per pixel (% $\Delta$ cpc)	
		Transaxial view	Coronal view	Transaxial view	Coronal view	Transaxial view	Coronal view
No asymmetry (5)	Normal	5.12 $\pm$ 2.45	4.43 $\pm$ 2.49	4.75 $\pm$ 1.91	3.88 $\pm$ 2.37	0.82 $\pm$ 0.76	1.34 $\pm$ 0.66
No further growth (9)	2 HH 7 HE	13.20 $\pm$ 14.27	12.79 $\pm$ 10.25	8.16 $\pm$ 10.93	7.23 $\pm$ 9.27	5.22 $\pm$ 4.08*	5.67 $\pm$ 3.88*
Growing (12)	8 HE 4 HH	46.52 $\pm$ 16.83**	37.67 $\pm$ 18.55**	34.71 $\pm$ 15.52**	27.84 $\pm$ 14.37**	15.05 $\pm$ 7.14**	12.29 $\pm$ 7.88**

Clinical status: as evaluated from dental cast and cephalograms. Difference: the percentage difference of isotope uptake between the condyles divided by the total uptake of the two condyles.

\*Significantly different from the normal patient at  $P < 0.05$ .

\*\*Significantly different from the patient with no further growth and normal patient at  $P < 0.05$ .

for the transaxial views and 0.78 for coronal views. Correlations between isotope uptake on these occasions ranged from 0.967 to 0.995 (Pearson correlation) for pixel count, isotope count and count per pixel.

Quantitative measurements of isotope uptake

The percentage difference in isotope uptake between the two condyles for all three parameters: the isotope count, pixel count and count per pixel, correlated with the clinical assessment as demonstrated by the Spearman rho (% $\Delta$ ic T,  $P = 0.85$ ; C,  $P = 0.72$ ; % $\Delta$ pc T,  $P = 0.81$ ; C,  $P = 0.77$ ; and % $\Delta$ cpc T,  $P = 0.86$ ; C,  $P = 0.72$ ). These percentage differences also correlated well with each other (Pearson  $r = 0.78-0.98$ ). The percentage difference measured from the transaxial views correlated well with that of the coronal views particularly for the measurement of count per pixel (count per pixel,  $r = 0.93$ , isotope count,  $r = 0.87$  and pixel count,  $r = 0.78$ ).

The data from the SPECT-mandible is shown in Table 2. The table groups the subjects according to the status of the mandibular growth (as assessed clinically:

normal, no further growth, growing), and shows the isotope measurements for both the transaxial and coronal projections. It presents the percentage difference in isotope count, pixel count and count per pixel between the two condyles as a ratio of the combined counts of both sides (% $\Delta$ ).

The percentage difference in isotope count (% $\Delta$ ic) and pixel count (% $\Delta$ pc) of the growing condyle group was significantly greater than the 'normal' group and the 'no further growth' group both in the transaxial and the coronal views. There was no significant difference between the normal group and no further growth group. For the percentage difference in count per pixel (% $\Delta$ cpc), there was a significant difference between the three clinical status groups in both the transaxial and the coronal views.

The percentage differences in count per pixel of the condyle (as measured from the transaxial view of each subject) are illustrated in Fig. 2. Those with a clinical status of growing condyles tended to show larger differences between the left and right condyles while the right-left differences among the normal patients were clustered together and averaged close to 0%.

Discussion

This report is a preliminary evaluation of the role of MDP-SPECT in delineating cessation of bone growth in unilateral condylar hyperplasia. An MDP planar scan was first reported nearly 20 years ago when KABAN et al.<sup>10</sup> examined differences between the left and right jaws in normal patients as a function of age. Subsequently, other investigators reported studies on normal and various abnormalities of the mandibular joints. The two condyles were evaluated using two lateral views necessitating normalizing the isotope deposit to a common vertebrae<sup>4,10</sup>, or else using the unaffected condyle as the reference anatomy<sup>1,5,7,13,17</sup>. Studies from planar bone scans have some limitations due to superimposition of the condyles with the petrous bone and mastoid process in the antero-posterior view, and overlapping with one another in the lateral view. SPECT is superior to planar scan because it can isolate the two condyles fairly accurately. Earlier studies on SPECT concentrated mainly on comparison with measurements from planar bone scans, and the clivus at the base of skull was used in SPECT instead of the lumbar vertebra as the reference point<sup>2,14</sup>.

Most reports<sup>2,4,10,14,17</sup> quantified isotope content by using the count per pixel when other structures such as the lumbar vertebra or the clivus were used as the reference point; the isotope count was used when the contralateral condyle was the reference point. Since isotope count and pixel count reflect basically the same quantity in nuclear medicine, our study used both parameters together with count per pixel and found the correlation more than 70% among them, suggesting similar usefulness in growth evaluation. Isotope count seems to be the most logical parameter since paired anatomical structures were compared; thus the count per pixel may not be necessary. However, the percentage difference in both isotope count (% $\Delta$ ic) and count per pixel (% $\Delta$ cpc) correlated well

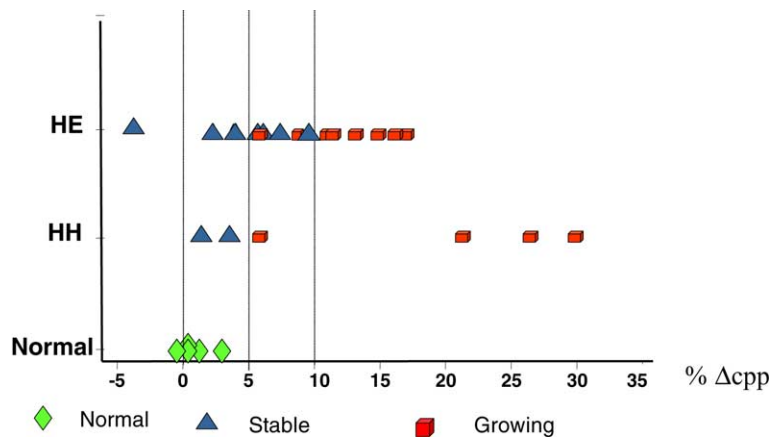


Fig. 2. Percentage difference of count per pixel (% $\Delta$ cpc) between the two condyles for each subject (transaxial view). HE: hemimandibular elongation, HH: hemimandibular hyperplasia.

with the clinical status, and better than the pixel count (% $\Delta$ pc). When detecting the differences among the three clinical status groups by using percentage difference, count per pixel (% $\Delta$ c<sub>pp</sub>) showed the best discrimination. Although the percentage differences of the three parameters correlated with each other, the cut-off point for discrimination still varied for each parameter. Previous studies<sup>1,4,8,10,14,17</sup> used differences between condylar uptake in normal jaws as a cut-off point to determine if condylar growth in the asymmetric condyle had ceased. This may underestimate the growth status in unilateral hyperplasia because, even when bone growth has ceased, the abnormal site may be enlarged and hence give a larger unequal isotope uptake.

One study by HODDER et al.<sup>8</sup> used SPECT to evaluate bone growth status in mandibular condylar hyperplasia by comparing the two condyles. They utilized 10% difference in isotope count of the condyles (% $\Delta$ ic) as a demarcation value for intervention and an indication of active condylar hyperplasia. A relative percentage of isotope uptake by the two condyles and a distribution of 55 versus 45 as the normal limit were used. In their study, 3 out of 11 patients had differences greater than 10% but two did not show a clinical progression of asymmetry within the year of follow up. Hence, the clinical validity of the 10% criterion needs further investigation.

In our study, the percentage differences of the three isotope parameters (% $\Delta$ ic, % $\Delta$ pc, % $\Delta$ c<sub>pp</sub>) were discriminatory enough to distinguish the uptake of the 'growing condyle' from the 'no further growth' condyle and the 'normal' condyle. The no further growth condyle had a wider range of isotope uptake from nearly normal to nearly growing, meaning that the affected condyle may stop growing but may be bigger in size, or may be slow growing so that it cannot be detected by clinical examination. The difference between the normal group and the no further growth group could be detected by the % $\Delta$ c<sub>pp</sub>, but not by the % $\Delta$ ic and the % $\Delta$ pc.

What the current study has attempted to do is to separate 'active growth' from 'growth cessation' based on clinical assessment and using only one SPECT. The result suggests that condylar isotope deposits for each pair of condyles differing by less than 10%, using any of the three isotope uptake parameters, can be regarded as within normal limits and may support the diagnosis of mandibular condylar hyperplasia where bone growth has ceased. The normal condyles showed a small difference between the two sides varying from 0 to 5% depend-

ing on the parameters used. A greater than 10% difference in the count per pixel, and 20–30% in the isotope count and pixel count, suggested that the bone was still growing and corrective surgery should be delayed or interceptive surgery offered if the condition was severe, particularly when a high difference was detected.

The number of patients in this study is small, and a large collection of patients should give more specific data. Either the isotope count or the count per pixel can be used as the quantitative measurement, but count per pixel gives a better correlation with clinical assessment than does isotope count. In summary, it can be concluded that a single measurement of mandibular MDP-SPECT using the percentage difference in the isotope uptake of the two condyles was accurate enough to separate 'active growth' from 'growth cessation' of the condyle; however, a longer follow-up period and a larger group of patients are needed to confirm this finding.

*Acknowledgements.* The authors would like to acknowledge the financial support of research funds from Prince of Songkla University. We wish to express our appreciation to Oral and Maxillofacial staff for their contribution during the follow-up period and for clinical assessment, and to Professor Nabil Samman, University of Hong Kong for his comments and suggestions.

## References

- BOHUSLAVIZKI KH, BRENNER W, KERSCHER A, FLEINER B, TINNEMEYER S, SIPPEL C, WOLF H, CLAUSEN M, HENZE E. The value of bone scanning in pre-operative decision-making in patients with progressive facial asymmetry. *Nucl Med Commun* 1996; **17**: 562–567.
- CHAN WL, CAROLAN MG, FERNANDES VB, ABBATI DP. Planar versus SPET imaging in the assessment of condylar growth. *Nucl Med Commun* 2001; **21**: 285–290.
- CISNEROS GJ. Update on skeletal scintigraphy. *Oral Maxillofac Surg Clin N Am* 1994; **6**: 101–111.
- CISNEROS GJ, KABAN LB. Computerized skeletal scintigraphy for assessment of mandibular asymmetry. *J Oral Maxillofac Surg* 1984; **42**: 513–520.
- GRAY RJ, HORNER K, TESTA HJ, LLOYD JJ, SLOAN P. Condylar hyperplasia: correlation of histological and scintigraphic features. *Dentomaxillofac Radiol* 1994; **23**: 103–107.
- GRAY RJ, SLOAN P, QUAYLE AA, CARTER DH. Histopathological and scintigraphic features of condylar hyperplasia. *Int J Oral Maxillofac Surg* 1990; **19**: 65–71.
- HENDERSON MJ, WASTIE ML, BROMIGE M, SELWYN P, SMITH A. Technetium-99 m bone scintigraphy and mandibular condylar hyperplasia. *Clin Radiol* 1990; **41**: 411–414.
- HODDER SC, REES JI, OLIVER TB, FACEY PE, SUGAR AW. SPECT bone scintigraphy in the diagnosis and management of mandibular condylar hyperplasia. *Br J Oral Maxillofac Surg* 2000; **38**: 87–93.
- IANNETTI G, CASCONI P, BELLI E, CORDARO L. Condylar hyperplasia: cephalometric study, treatment planning, and surgical correction (our experience). *Oral Surg Oral Med Oral Pathol* 1989; **68**: 673–681.
- KABAN LB, CISNEROS GJ, HEYMAN S, TREVES S. Assessment of mandibular growth by skeletal scintigraphy. *J Oral Maxillofac Surg* 1982; **40**: 18–22.
- MATTESON SR, PROFFIT WR, TERRY BC, STAAB EV, BURKES -EJJ.. Bone scanning with 99mtechnetium phosphate to assess condylar hyperplasia. Report of two cases. *Oral Surg Oral Med Oral Pathol* 1985; **60**: 356–367.
- OBWEGESER HL, MAKEK MS. Hemimandibular hyperplasia-hemimandibular elongation. *J Maxillofac Surg* 1986; **14**: 183–208.
- POGREL MA. Quantitative assessment of isotope activity in the temporomandibular joint regions as a means of assessing unilateral condylar hypertrophy. *Oral Surg Oral Med Oral Pathol* 1985; **60**: 15–17.
- POGREL MA, KOPF J, DODSON TB, HATTNER R, KABAN LB. A comparison of single-photon emission computed tomography and planar imaging for quantitative skeletal scintigraphy of the mandibular condyle. *Oral Surg Oral Med Oral Pathol Oral Radiol Endod* 1995; **80**: 226–231.
- PROFFIT WR, ACKERMAN JL. Diagnosis and treatment planning in orthodontics. In: GRABER TM, VANARSDALL RT, eds: *Orthodontics Current Principles and Techniques* 2nd edn. St Louis: Mosby 1994: 3–95.
- RAKOSI T. Cephalometric radiography and growth. In: RAKOSI T, ed: *An Atlas and Manual of Cephalometric Radiography*. Philadelphia: Lea & Febiger 1982 34–45.
- ROBINSON PD, HARRIS K, COGHLAN KC, ALTMAN K. Bone scans and the timing of treatment for condylar hyperplasia. *Int J Oral Maxillofac Surg* 1990; **19**: 243–246.

Address:  
 Prisanna Pripatnanont  
 Department of Oral and Maxillofacial Surgery  
 Faculty of Dentistry  
 Prince of Songkla University  
 Hatyai  
 Songkhla, 90112  
 Thailand  
 Tel: +66 74 429876  
 Fax: +66 74 429876  
 E-mail: prisana.p@psu.ac.th