

Research Report

Proportion of deproteinized bovine bone and autogenous bone affects
bone formation in the treatment of calvarial defects in rabbits

For a fulfillment of a university grant 2006

January 2006 – May 2007

Assoc. Prof. Prisana Pripatnanont

Department of Oral and Maxillofacial Surgery,
Faculty of Dentistry,
Prince of Songkla University,
Hat Yai,
Songkhla 90112

Table of Contents

Author & Correspondent	3
Abstract	4
Introduction	5
Materials and methods	8
Animals	8
Material	9
Surgical Procedure	10
Radiograph	12
Histology processions	12
Histomorphometric analysis	13
Data analysis	14
Results	15
Radiographic features	15
Histology	18
Histomorphometry	22
Discussion	24
Conclusion	26
Acknowledgments	26
References	27
Manuscript	30

Proportion of deproteinized bovine bone and autogenous bone affects in bone formation in the treatment of rabbits' calvarial defects

Prisana Pripatnanont, DDS*, Thongchai Nuntanaranont, DDS, MD, MSc*,
Surapong Vongvatcharanon, DDS, MD†

*Associate Professor, †Assistant Professor, Department of Oral and Maxillofacial Surgery, Faculty of Dentistry, Prince of Songkla University, Hatyai, Songkla, Thailand.

Corresponding author:

Associate Professor Prisana Pripatnanont, DDS

Department of Oral and Maxillofacial Surgery,

Faculty of Dentistry,

Prince of Songkla University,

Hatyai, Songkhla, 90112

Thailand

Tel no. 66-74-429876

Fax no. 66-74-429876

Email: prisana.p@psu.ac.th

Presented at the 7th Asian Congress on Oral & Maxillofacial Surgery, November 5-9 2006, Hong Kong, China.

This research was funded by the Thailand Government Fund, Thailand.

Proportion of deproteinized bovine bone and autogenous bone affects in bone formation in the treatment of rabbits' calvarial defects

Abstract:

This study aimed to assess new bone formation generated using three different proportions of autogenous bone (AB) and deproteinized bovine bone (DBB). Thirty bicortical skull defects were prepared in 15 rabbits, divided into 3 groups: Group 1, critical size defect (CSD) versus AB as controls; Group 2, DBB versus a composite of AB and DBB using a proportion of 1:1; and Group 3, a composite of AB and DBB using a proportion of 1:2 versus a proportion of 1:4. After sacrificed at eight weeks, radiographic evaluation was performed by densitometry analysis and new bone formation by histomorphometry analysis. The mean optical density of the CSD (0.108 ± 0.238) and AB (0.352 ± 0.161) groups differed significantly from the DBB group (1.044 ± 0.093) and the groups using a proportion of 1:1 (0.905 ± 0.078), 1:2 (0.865 ± 0.294) and 1:4 (0.867 ± 0.304). The histomorphometry analysis demonstrated higher percentage of new bone in the AB group (30.223 ± 16.722) than in the groups using proportions of 1:2 (22.639 ± 5.659), 1:1 (20.929 ± 6.169), 1:4 (9.621 ± 2.400), DBB (14.441 ± 2.742) and CSD (10.645 ± 8.868) respectively. The 1:2 group had significantly higher bone content than the 1:4 group. The proportions of 1:1 and 1:2 resulted in greater bone formation than the proportion of 1:4, the DBB and the CSD.

Key words: autogenous, bovine hydroxyapatite, composite graft, deproteinized bovine bone, graft

Proportion of Deproteinized Bovine Bone and Autogenous Bone affects in bone formation in the treatment of rabbits' calvarial defects.

Introduction

The treatment of craniofacial and maxillofacial deformities and defects has a long history of experimentation with various grafts. The ideal bone graft should be osteoinductive to stimulate osteogenesis and osteoconduction and provide a scaffold for establishing optimal conditions for in-growth of blood vessels and cells with osteogenic potential and not induce immunological rejection. Although these requirements are currently most adequately fulfilled by autogenous bone grafts, donor site morbidity and its limited volume indicate a need to develop substitute materials for autogenous bone. Deproteinized bovine bone (DBB) is one bone substitute that has a structure similar to human bone and has properties of osteoconduction and biocompatibility (Piattelli, et al., 1999). The addition of osteoconductive materials in composite graft, can expand the volume, induce dense new bone formation and prevent premature resorption at the augmented site. Therefore the amount of autogenous bone needed will be decreased and donor site morbidity is alleviated (Boyne, 1997); (Hallman, et al., 2001a; Hallman, et al., 2001b; Hallman, et al., 2002b; Hallman, et al., 2002a) (Kasabah, et al., 2002) (Merks, et al., 2003); (Tadjoedin E.S., et al., 2003). Bovine hydroxyapatite or deproteinized bovine bone is a bone substitute material. Organic part can be removed by heat or chemical agent. Its structure is porous, well-interconnected pore structure and the pore sizes are in the range of 200-500 μm , which can provide a scaffold for vascular and osteogenic cell ingrowth. Deproteinized bovine bone has been used successfully to fill bone defects, particularly in maxillary sinus floor grafting to facilitate dental implants. However, it has a slow resorption rate (Schlegel, et al., 2003), resulting in a slow process of complete bone formation. A combination of autogenous and deproteinized bovine bone in appropriate proportions would be an effective choice for bone grafting.

The composite of autogenous bone and bone substitute (Al Ruhaimi, 2001), is widely used in clinical settings because it combines the osteogenesis property of autogenous bone and the osteoconductive property of DBB, and therefore contains osteogenic cells and

provides a scaffold and internal pores for bone cells to grow and eventually remineralize to new bone(Boyne, 1997). At present, the relative proportions of autogenous bone and bone substitute are varied (Table 1). Several studies have preferred a composite of autogenous bone and DBB in a 1:4 proportion mixed with fibrin glue for sinus grafting, and found that this proportion was not significantly different from autogenous bone or DBB alone in terms of bone healing and osseointegration(Hallman, et al., 2002b;Hallman, et al., 2001a;Hallman and Nordin, 2004). Boyne used particulate marrow and cancellous bone (PMCB) mixed with Bio-Oss® (Geistlich pharma AG, Switzerland) in a 1:1 proportion for the treatment of atrophic maxilla and achieved a good result with less bone resorption(Boyne, 1997). However, other studies have used various proportions such as of 1:1, 1:2 and 1:4 and each report claimed that each proportion achieved good clinical results (Boyne, 1997;Maiorana, et al., 2000) ;(Hallman, et al., 2002b). A systematic review by Merkx recommended the proportion of 1:2 (Merkx, et al., 2003). Until now, no report has been published comparing each proportion directly both in clinical studies and animal testing for effective new bone formation (Hallman, et al., 2001a;Maiorana, et al., 2000);(Tadjoedin E.S., et al., 2003) .

Table 1. Summary of previous recommended proportion of autogenous to deproteinized bovine bone for composite graft

Authors	Article	Type of graft	Autogenous:DBB
Boyne 1997	Case report	Bone augmentation in atrophic maxilla	1:1
Maiorana 2001	Case report	Bone augmentation in atrophic maxilla	1:1
Hallman 2001, 2002, 2004	Clinical trial	Sinus graft	1:4
Merkx 2003	Systematic review	Sinus graft	1:1 to 1:2
Hatano 2004	Clinical report	Sinus graft	2:1

The present study aimed to assess the quality and quantity of new bone formation using the three different proportions (1:1, 1:2 and 1:4) of autogenous bone and deproteinized bovine bone in rabbit calvarial defects.

Materials and methods

Animals

This study was performed in accordance with the regulations and with the approval of the Animal Experiment Ethics Committee of Prince of Songkla University. Fifteen male New Zealand white rabbits aged 5-7 months each weighing between 3 and 4 kilograms were used for the study (Fig 1). The animals were divided into 3 groups: Group 1 as a control group comprised of a critical size defect (CSD) versus autogenous bone chips, and Groups 2 and 3 as experimental groups. Group 2 used DBB alone versus a composite of autogenous bone and DBB in a proportion of 1:1 and Group 3 used a composite of autogenous bone and DBB in a proportion of 1:2 versus a proportion of 1:4 (Table1). The animals were kept in single cages and fed a standard dried diet and water ad libitum.

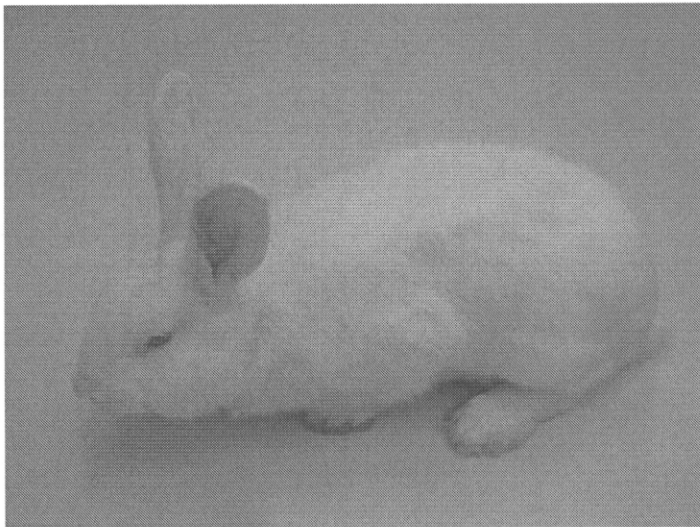

Fig 1. New Zealand white rabbits

Table 1. Group of study design

Group	Material (N = 5 defects)	Material (N = 5 defects)
Group I: Control 5 rabbits	Critical size defect (CSD)	Autogenous
Group II: Experiment 1 5 rabbits	Deproteinized bovine bone (DBB)	1:1 ratio Autogenous:DBB
Group III: Experiment 2 5 rabbits	1:2 ratio Autogenous:DBB	1:4 ratio Autogenous:DBB

Material

Deproteinized bovine bone derived from heat treatment at 1200^o C with grain sizes of 0.25-1mm was obtained from the Metal and Material Technology Center, Thailand. It has been shown to be an osteoconductive material in our previous study. It has porous, well-interconnected pore structure with pore size approximately 200-500 μm (Pripatnanont, et al., 2007) (Fig 2,3).

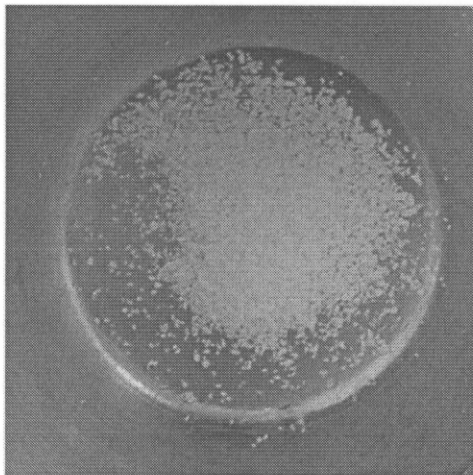


Fig2. Deproteinized bovine bone particle




Fig 3. SEM photographs of DBB granules showing the pore structure, size 200-500 μm (original magnification, X400)

Surgical Procedure

Anesthesia was induced using Ketamine 25mg/kg and diazepam 5 mg/kg intramuscularly 30 minutes prior to the operation. Thiopental 5 mg/kg was administered intravenously and then titrated at the rate of 2 mg/kg every 15 minutes (with a maximum dose of no more than 30 mg/kg) until unconsciousness was achieved.

The surgical field was disinfected with Povidone-iodine 10%. A mid-sagittal incision was performed after local infiltration of 2% lidocaine HCL with 1:100,000 epinephrine 1.8 ml. Subperiosteal dissection was carried out, and 2 bicortical bone defects of 10x10mm were prepared with a small round bur and a fissure bur using a micro motor. A sterilized aluminum template was used as a template guide to ensure the same size of the defect in each animal. A 1mm deep circular mark was made with a small round bur and filled with preheated gutta percha for later identification of the defect edges on the histological sections. In the control group, autogenous bone from the removed calvarium was minced with a bone morselizer (Salvin Dental Specialties Inc, Charlotte, NC, USA) and then inserted in one side of the defect.

The bone morselizer has a 10 mm knurled titanium surface with 1.5 mm serrated size, used for crushing bone into small homogeneous pieces to be filled in each defect. The contra lateral side was left empty for a negative control of the critical size defect (Schmitz and Hollinger, 1986). In the experimental groups, DBB was soaked with normal saline and mixed with minced autogenous bone from the removed calvarium in different proportions (autogenous:DBB at proportions by weight of 1:1, 1:2 and 1:4 to achieve a total weight of 0.24 mg) and were inserted into the defects (Fig. 4). Subsequently, the periosteum, the muscle and the skin were sutured. After 8 weeks, the animals were sacrificed with an overdose (1.2-1.3 ml) of pentobarbital sodium 200mg/ml administered intravenously. The calvarium was then removed in one piece and fixed in 10% formalin and submitted to radiographic and microscopic analysis for histomorphometric analysis.

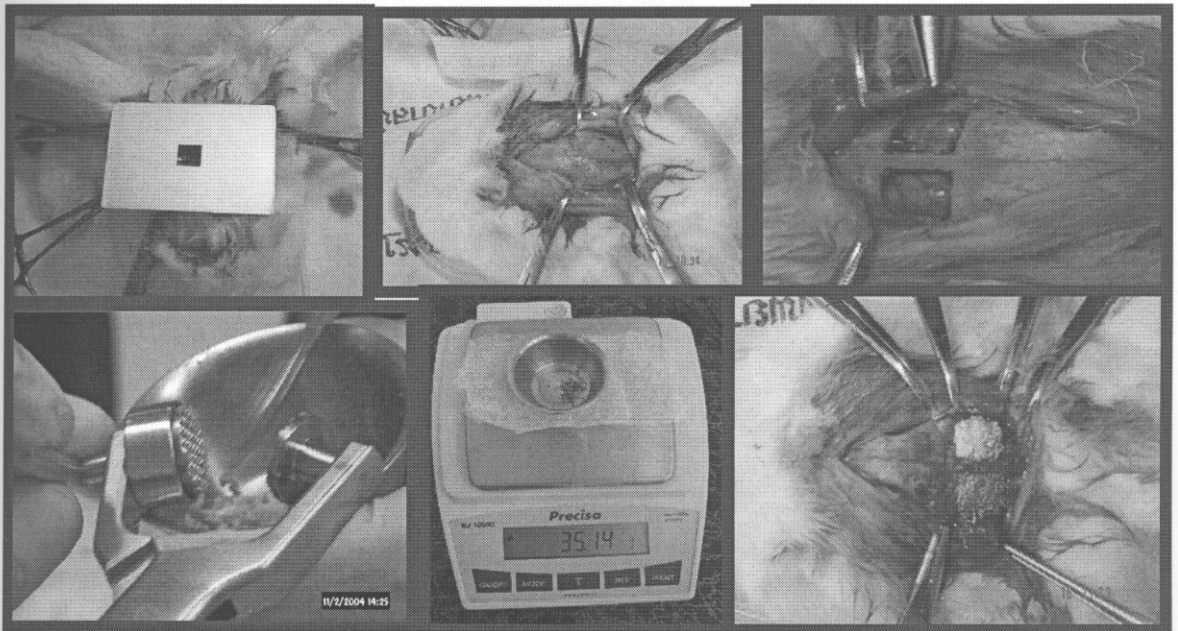


Fig4. Surgical procedures to create rabbit's calvarial defect and grafting procedures.

Radiograph

To obtain radiographic images of the specimens, the radiographs were exposed with 40-cm dff, 10 mA, 50kvp for 0.42 sec (GX 1000; Gendex Model, Milwaukee, WI, USA). An aluminum step wedge was used for calibration. The images were scanned into the computer with Bio-Rad's Densitometer GS-700 (Bio-Rad, Hercules, CA, USA), and the mean optical density (OD) was calculated and analyzed using Image Pro Plus 5.0 (Media Cybernetics; Silver Spring, MD, USA) (Fig 5).




Fig 5. Scanned radiograph for densitometry analysis

Histology processing

Following radiography, the calvarial specimens were decalcified in formic acid, trimmed, and cut transversally into upper, middle and lower parts and then embedded in paraffin (Fig 6). Serial sections in 5 μ m were cut from each part and stained with hematoxylin and eosin. All slides were examined descriptively before histomorphometric analysis.




Fig 6. Calvarial specimen

Histomorphometric analysis

The middle parts of the sections used for histomorphometric analysis were the same parts as those used for examining histology. They were analyzed by the same examiner using an image analysis system which measured the percentages of newly-deposited bone. The system consists of an infinity-corrected light microscope (Axiostar; Carl Zeiss, Göttingen, Germany), with objective achromatic 5X and eyepiece 10X, a high resolution digital camera (Axiocam mRC model; Carl Zeiss) with adapter 0.63X to fit the field of view, an image capture device (Axioversion; Carl Zeiss), and a computer-based image processor for histomorphometry (Image Pro Plus 5.0; Media Cybernetics, MD, USA) (Fig 7).

Images of newly formed bone were identified by a given color in each image. These were digitized and transferred to the computer software for image processing and analysis of the quantity fraction of the total area of the defect by the formula as follows:

$$\% \text{ New bone} = \frac{\text{Area of new bone in the defect} \times 100}{\text{Total area of the defect}}$$

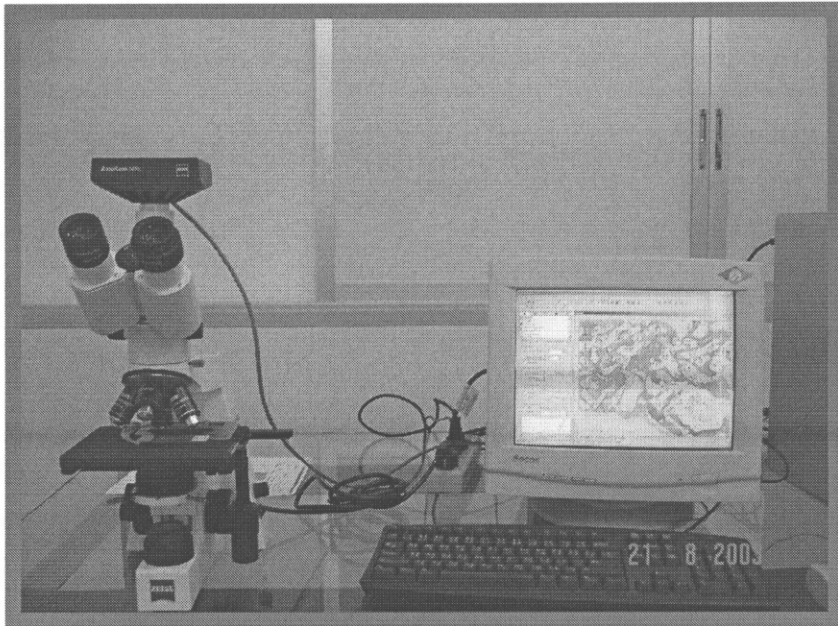


Fig 7. Histomorphometry analysis

Data analysis

Data analysis was conducted using SPSS 14.0 (SPSS Inc, Chicago, IL, USA). Data were tested for normality and one-way analysis of variance and multiple comparison using Tukey HSD test or Dunnett T3 ($p < 0.05$) were then carried out to compare the differences between the mean ODs and the percentages of newly formed bone among the groups.

Results

Radiographic features

Control group:

Critical size defect: The homogenous radiolucent area was observed to consist almost entirely of bony defect (Fig. 3A).

Autogenous bone chips: A radiopaque mass of bone chips of different sizes and density were observed in the defect. A homogeneous radiopaque area around the edge of the defect with similar density to normal bone had appeared (Fig. 3A).

Experimental groups:

A well-delineated radiopaque area of bone defect was observed. The bone defects were filled with the distinct radiopaque granules of DBB. The defect treated with DBB alone was more radiopaque than those treated with proportions of 1:1, 1:2 and 1:4, which had similar densities (Fig. 3B, C).

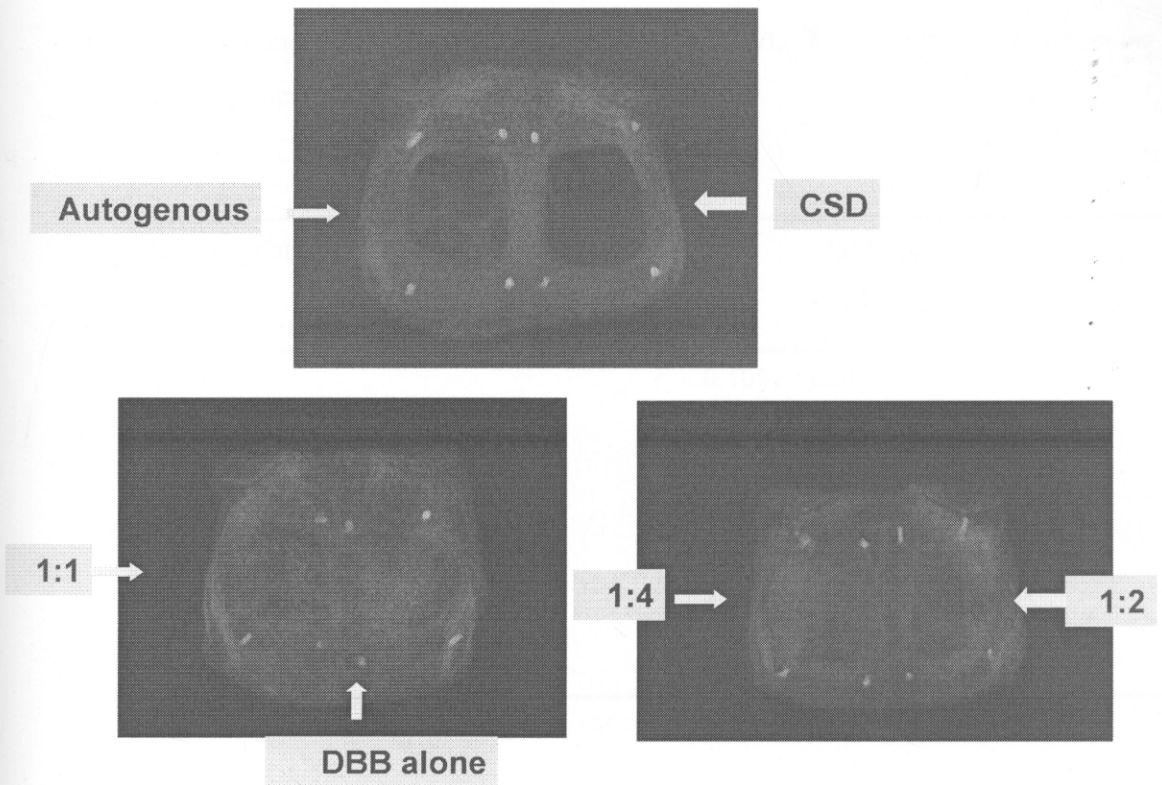


Fig 8. Photograph of the occlusal films of the rabbits' calvarium. (A) An autogenous at the left side and critical size defect at the right side. (B) A composite graft of autogenous bone and DBB at 1:1 ratio at the left side and DBB alone at the right side. (C) A composite graft of autogenous bone and DBB at 1:4 ratio at the left side and a composite graft of autogenous bone and DBB at 1:2 ratio at the right side

Detailed computer-assisted analysis of the radiographic films is shown in Figure 4, but no difference between the DBB granules and new bone formation could be discerned. The mean optical density (OD) of the CSD (0.108 ± 0.238) and autogenous bone chips (0.352 ± 0.161) was found to be significantly lower than that of DBB alone (1.044 ± 0.093) and the proportion of 1:1 (0.905 ± 0.078), 1:2 (0.865 ± 0.294) and the 1:4 (0.867 ± 0.304) (ANOVA, $F=14.870$; $df = 5, 24$; $p = 0.000$) (Table 2, Fig 9). However, the differences between the mean ODs of each experimental group were not statistically significant.

Table 2. Mean optical density \pm standard deviation, * Significant different from the autogenous group and the CSD at $p < 0.05$

Study group	Optical density (mean \pm SD)
CSD	0.108 \pm 0.238
Autogenous	0.352 \pm 0.161
DBB	1.044 \pm 0.093*
Auto:DBB 1:1	0.905 \pm 0.078*
Auto:DBB 1:2	0.865 \pm 0.294*
Auto:DBB 1:4	0.690 \pm 0.304*

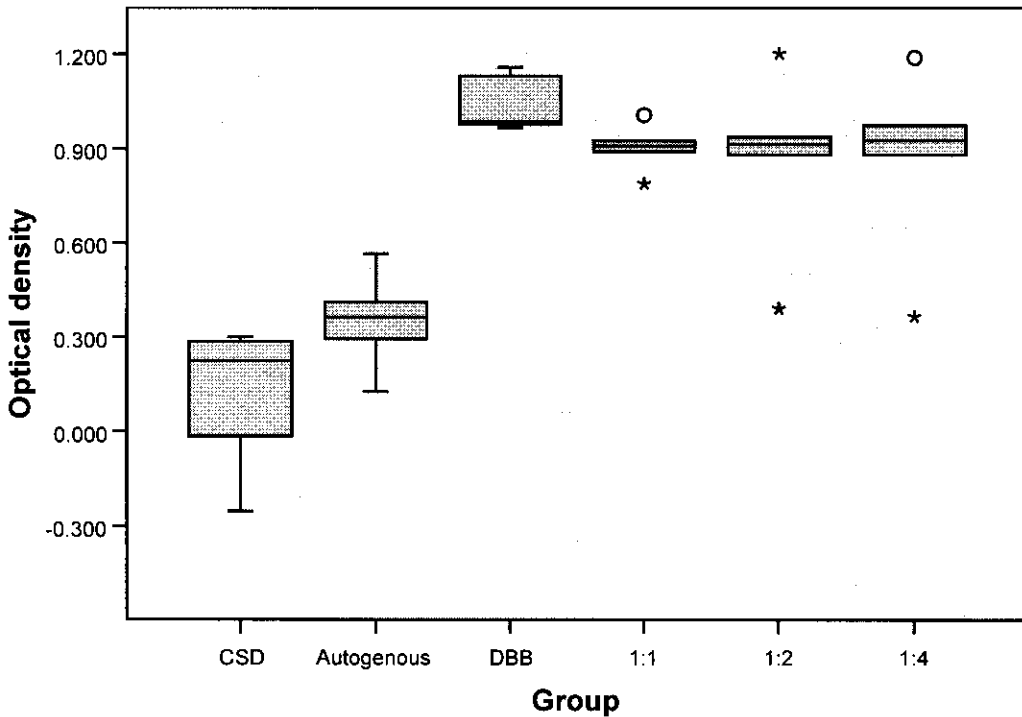


Fig 9. Mean optical density of rabbit's calvarium specimens

Histology

Critical size defect: The defect was filled with narrow band of loose connective tissue and a little newly formed bone projecting from the defect edge. The contour of the defect was collapsed (Fig. 10A, 11A).

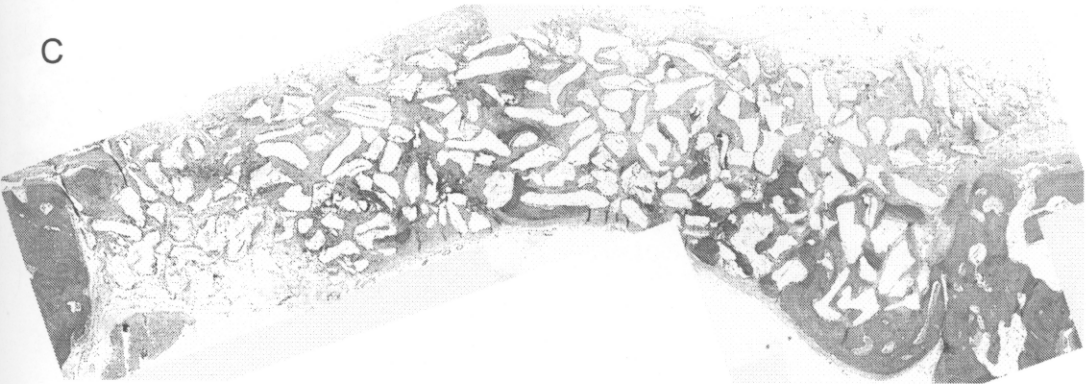
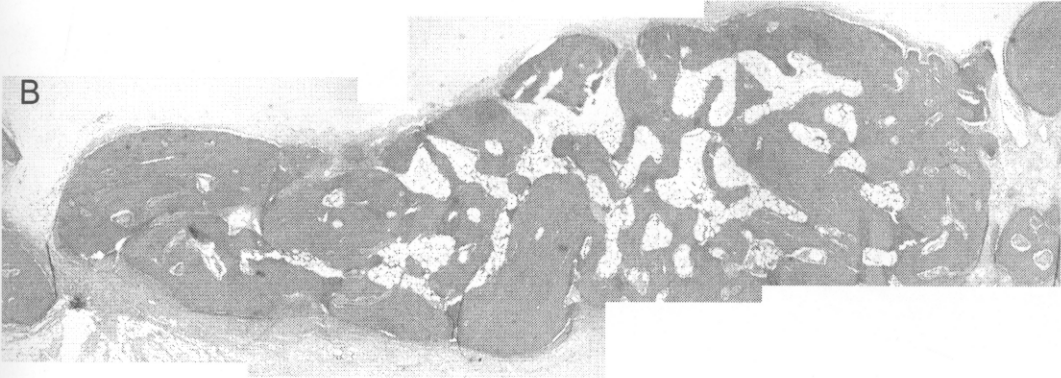Autogenous bone chips: The defect was filled with autogenous bone chips and newly formed bone, which combined well with each other and bridged the defect with full contour. (Fig. 10B, 11B).

DBB alone: The defect of the DBB specimen was filled with particles and newly formed bone projected from the defect edge, extending centripetally and combining well with the particles, and a little new bone was found in the central part of the defect. The particles and new bone bridged the defect with full contour (Fig. 10C, 11C).

Proportion 1:1: The defect was filled with complete bone bridging along the defect, generating newly formed bone throughout the defect. New bone combined well with the autogenous bone chips and filled the defect with full contour (Fig. 10D, 11D).

Proportion 1:2: The defect presented newly formed bone projecting from the bone edge. At the bone margin, newly formed bone combined well with the DBB particles and autogenous bone chips. Some new bone formation was found in the central part of the defect. The grafting material filled the defect with normal contour (Fig. 10E, 11E).

Proportion 1:4: The defect presented little newly-formed bone projecting from the bone edge with a modest degree of combination with the DBB particles. In the central part, less bone formation was observed than in the other experimental groups. However, the grafting material still filled the defect with normal contour (Fig. 10F, 11F).



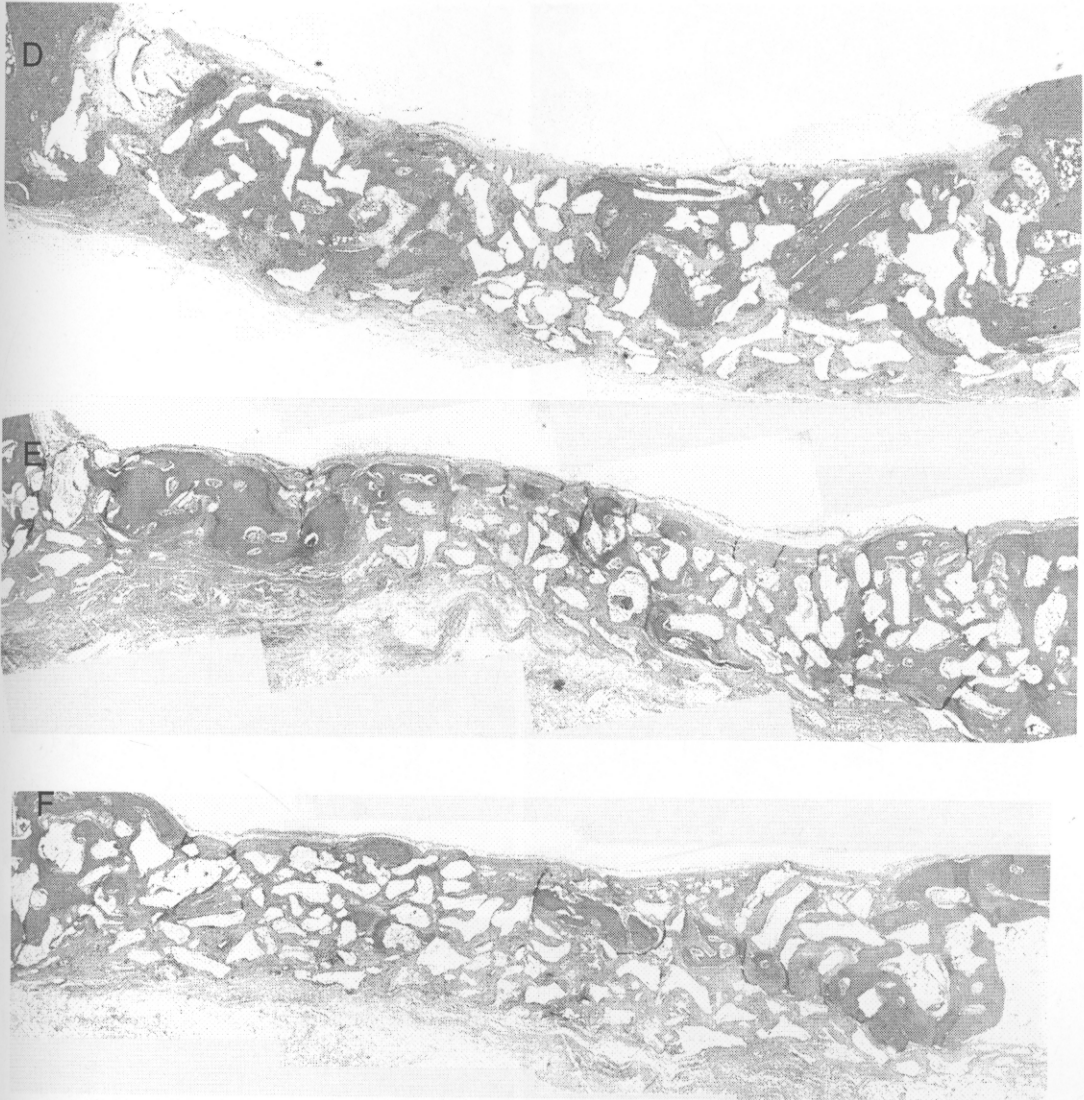


Fig. 10: Micrograph of each specimen (Hematoxylin and Eosin, original magnification x5)
(A) A critical size defect (B) An autogenous bone chip (C) DBB alone (D) A composite graft of autogenous bone and DBB at 1:1 ratio (E) A composite graft of autogenous bone and DBB at 1:2 ratio (F) A composite graft of autogenous bone to DBB at 1:4 ratio

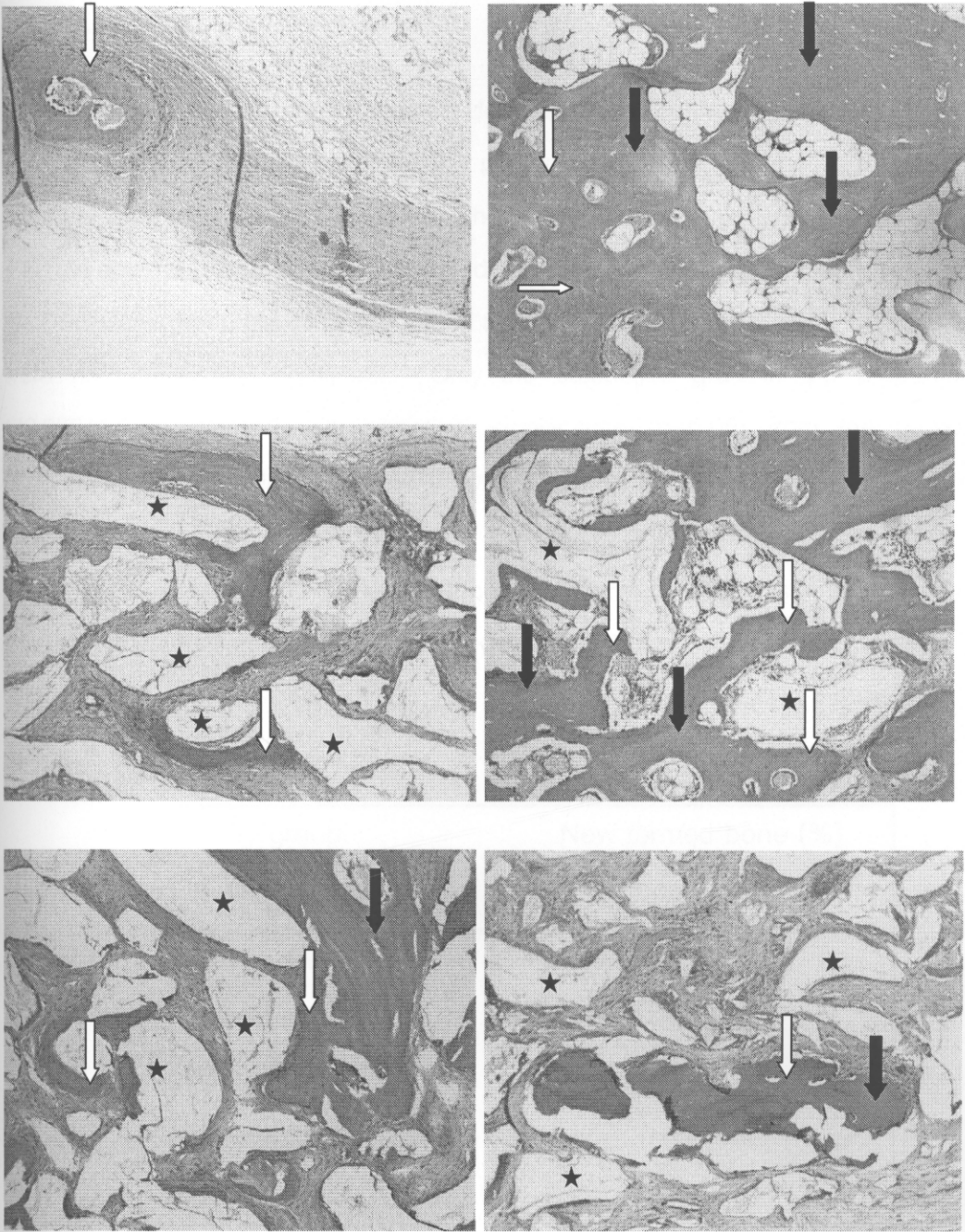


Fig. 11: (A) A critical size defect (B) An autogenous bone chip (C) DBB alone (D) A composite graft of autogenous bone and DBB at 1:1 ratio (E) A composite graft of autogenous bone and DBB at 1:2 ratio (F) A composite graft of autogenous bone to DBB at 1:4 ratio. White arrows indicate new bone, black arrows indicate bone chips, black stars indicate DBB particles. (Hematoxylin and Eosin, original magnification x10)

Histomorphometry

The histomorphometric analysis demonstrated that the bone defect implanted with autogenous bone chips (30.223 ± 16.722) presented more bone formation than other groups but there was no statistical significance. The composite grafts in the proportions of 1:1 (20.929 ± 6.169) and 1:2 (22.639 ± 5.659) presented larger quantities of bone tissue when compared to the DBB alone group (14.441 ± 2.742) and the CSD group (10.645 ± 8.868), although the results were not statistically significant. Only the composite graft in the proportion of 1:2 (22.639 ± 5.659) differed with statistical significance ($p < 0.05$) from the proportion 1:4 (9.621 ± 2.400) (Dunnett T3, MD=13.018; $p=0.039$) (Fig. 12, Table 3).

Table 3. Mean \pm standard deviation of new bone formation from histomorphometry, † Significant difference from the composite of autogenous and DBB at 1:4 ratio group at $p < 0.05$

Study group	New formed bone (%) (mean \pm SD)
CSD	10.645 \pm 8.868
Autogenous	30.223 \pm 16.722
DBB	14.441 \pm 2.742
Auto:DBB 1:1	20.929 \pm 6.169
Auto:DBB 1:2	22.639 \pm 5.659 †
Auto:DBB 1:4	9.621 \pm 2.400

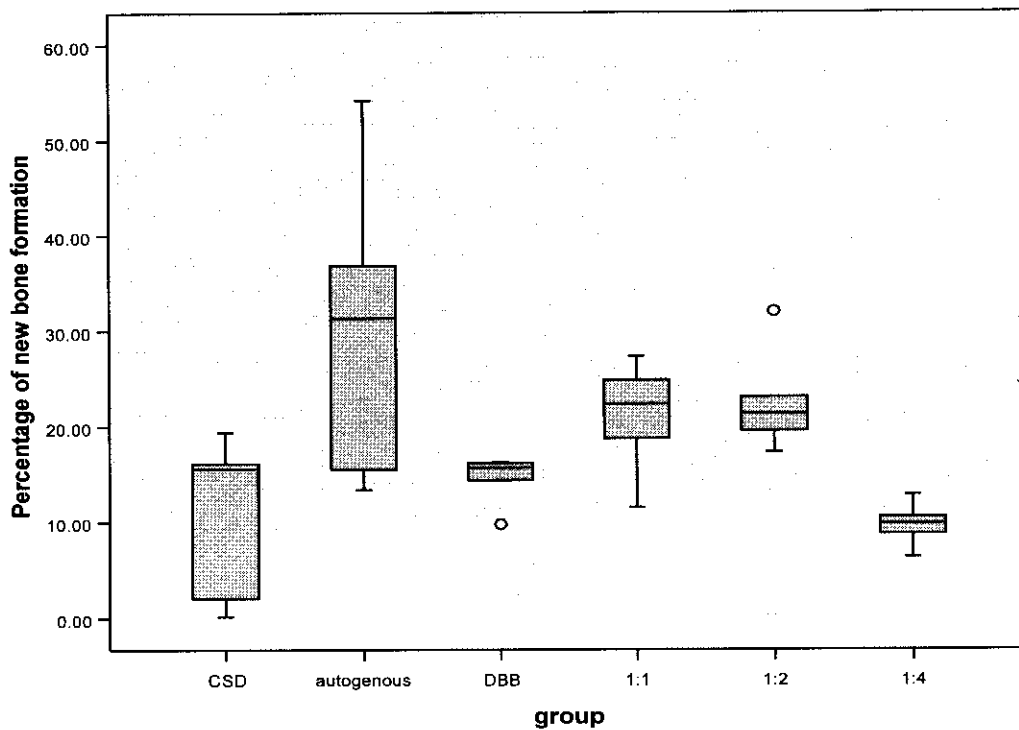


Fig. 12: Percentage of new bone formation from histomorphometry analysis

Discussion

This study aimed to compare the percentages of new bone formation generated by three different proportions of autogenous bone and DBB using histomorphometry. The extent of new bone formation for all groups in this study was less than bone formation observed in other studies (Hallman, et al., 2002b), which may be due to the fact that the amounts of bone packed into the rabbits' calvarial defects were calculated by weight, whereas in other studies they were calculated by volume. The calculation of proportions by weight results in a lower volume of fresh autogenous bone than dry DBB because it contains blood and is soaked with normal saline solution during the operation, resulting in a greater total weight which does not represent the net weight of the autogenous bone and contains fewer bone cells. However, proportion calculated by weight is a more accurate and consistent method of measurement when compared with proportion calculated by volume.

The rabbit was used in this experiment because its physiologic bone healing is like that of human but the rate of healing is 3 times higher than in human. There were also other reasons for using rabbits such as the availability of the animal, the effective accessibility to the calvarial defects, easier to manipulation than other big animals and ethical acceptance was possible. We chose 8 weeks time as the end point to observe bone formation since it represented the remodeling phase of bone healing in a rabbit which is long enough to prove the property of CSD that no complete bone healing occurred and to ensure the capability of bone formation in the experimental group. Based on the fact that the physiologic bone healing of a rabbit is 3 times faster than in human, 8 weeks can be compared to 6-8 months in human which is relevant to clinical practice because it is the same course of time in bone grafting particularly in sinus grafting(Shirota, et al., 1996).

In the past, Bio-Oss[®], which is a deproteinized cancellous bovine bone treated using a chemical agent, was widely used as a bone substitute because its structure is similar to that of human bone and many studies claimed its properties of osteoconduction and biocompatibility were beneficial to the human body(Boyne, 1997;Fukuta, et al., 1992;Piattelli, et al., 1999;Schlegel, et al., 2003). Although this study used DBB which was heat treated at

1200°C, the histology result shows the osteoconductive property and biocompatibility of this material.

While several studies have used the proportions of 1:1 and 1:2 for clinical use, they each presented only one proportion and evaluated the clinical results or the histology of bone implant contact but did not carry out a histomorphometric analysis(Boyne, 1997;Maiorana, et al., 2000;Merkx, et al., 2003). However, Hallman et al. used the proportion of 1:4 compared with autogenous bone alone and deproteinized cancellous bovine bone alone (Hallman, et al., 2002b)(Tadjoedin E.S., et al., 2003) and proposed that a 1:4 proportion could enhance bone formation of a quality similar to autogenous bone.

The results of our study have proved that the proportions of 1:1 and 1:2 enhance bone formation in comparison with the proportion of 1:4 and DBB alone. Although the level of new bone formation observed using 1:1 and 1:2 proportions was less than that observed in the autogenous group, they still have some advantages in terms of the slow resorption rate of the grafted area, bridging of the defect with full contour, and definitely lower morbidity of the donor site.

This study demonstrated only the difference between the 1:2 proportion and the 1:4 proportion in histomorphometry, which confirms that the 1:1 and 1:2 proportions are better than 1:4 in terms of new bone formation. The differences between other groups could not be demonstrated because of wide variations in the data, particularly in the autogenous group and the CSD group. Furthermore, in the CSD group the defect was not filled so there was only a narrow band of fibrous tissue presented. As the total area in the CSD group was collapsed and therefore smaller than that of the other filled defect groups, the estimated percentage of new bone somewhat overestimated than the actual amount of new bone. Although significance differences in each proportion of new bone in the tested and the control were not found, the ability of the composite graft to promote new bone formation and fill the defect could be demonstrated qualitatively. The proportions of 1:1 and 1: 2 seem reliable when compared with the other proportions in terms of new bone formation. The composite graft of autogenous bone and deproteinized bovine bone are able to bridge the defect and also give a normal contour.

Conclusion

This study indicated that DBB enhanced bone formation and a composite graft of autogenous bone and DBB in the proportions of 1:1 and 1:2 should be preferred over other proportions for clinical use.

Acknowledgments

This study was funded by the Thailand Government Fund and Prince of Songkla University Thailand. The authors thank Professor Henk Tideman and Dr. Alan Geater, Prince of Songkla University, for his proof reading and advice.

References

1. Al Ruhaimi KA (2001) Bone graft substitutes: a comparative qualitative histologic review of current osteoconductive grafting materials. *Int J Oral Maxillofac Implants* 16:105-114.
2. Boyne PJ (1997) *Osseous reconstruction of the maxilla and the mandible*. Quintessence, Chicago.
3. Fukuta K, Har-Shai Y, Collares MV, Lichten JB and Jackson IT (1992) Comparison of inorganic bovine bone mineral particles with porous hydroxyapatite granules and cranial bone dust in the reconstruction of full-thickness skull defect. *J Craniofac Surg* 3:25-29.
4. Hallman M, Cederlund A, Lindskog S, Lundgren S and Sennerby L (2001a) A clinical histologic study of bovine hydroxyapatite in combination with autogenous bone and fibrin glue for maxillary sinus floor augmentation. Results after 6 to 8 months of healing. *Clin Oral Implants Res* 12:135-143.
5. Hallman M, Hedin M, Sennerby L and Lundgren S (2002a) A prospective 1-year clinical and radiographic study of implants placed after maxillary sinus floor augmentation with bovine hydroxyapatite and autogenous bone. *J Oral Maxillofac Surg* 60:277-284.
6. Hallman M, Lundgren S and Sennerby L (2001b) Histologic analysis of clinical biopsies taken 6 months and 3 years after maxillary sinus floor augmentation with 80% bovine hydroxyapatite and 20% autogenous bone mixed with fibrin glue. *Clin Implant Dent Relat Res* 3:87-96.
7. Hallman M and Nordin T (2004) Sinus floor augmentation with bovine hydroxyapatite mixed with fibrin glue and later placement of nonsubmerged implants: a retrospective study in 50 patients. *Int J Oral Maxillofac Implants* 19:222-227.

8. Hallman M, Sennerby L and Lundgren S (2002b) A clinical and histologic evaluation of implant integration in the posterior maxilla after sinus floor augmentation with autogenous bone, bovine hydroxyapatite, or a 20:80 mixture. *Int J Oral Maxillofac Implants* 17:635-643.
9. Kasabah S, Simunek A, Krug J and Lecaro MC (2002) Maxillary sinus augmentation with deproteinized bovine bone (Bio-Oss) and Impladent dental implant system. Part II. Evaluation of deproteinized bovine bone (Bio-Oss) and implant surface. *Acta Medica (Hradec Kralove)* 45:167-171.
10. Maiorana C, Redemagni M, Rabagliati M and Salina S (2000) Treatment of maxillary ridge resorption by sinus augmentation with iliac cancellous bone, anorganic bovine bone, and endosseous implants: a clinical and histologic report. *Int J Oral Maxillofac Implants* 15:873-878.
11. Merckx MA, Maltha JC and Stoelinga PJ (2003) Assessment of the value of anorganic bone additives in sinus floor augmentation: a review of clinical reports. *Int J Oral Maxillofac Surg* 32:1-6.
12. Piattelli M, Favero GA, Scarano A, Orsini G and Piattelli A (1999) Bone reactions to anorganic bovine bone (Bio-Oss) used in sinus augmentation procedures: a histologic long-term report of 20 cases in humans. *Int J Oral Maxillofac Implants* 14:835-840.
13. Pripatnanont P, Nuntanaranont T, Vongvatcharanon S and Limlertmongkol S (2007) Osteoconductive effects of 3 heat-treated hydroxyapatites in rabbit calvarial defects. *J Oral Maxillofac Surg* 65:2418-2424.
14. Schlegel KA, Fichtner G, Schultze-Mosgau S and Wiltfang J (2003) Histologic findings in sinus augmentation with autogenous bone chips versus a bovine bone substitute. *Int J Oral Maxillofac Implants* 18:53-58.

15. Schmitz JP and Hollinger JO (1986) The critical size defect as an experimental model for craniomandibulofacial nonunions. *Clin Orthop Relat Res* **205**:299-308.
16. Shirota T, Ohno K, Motohashi M and Michi K_I (1996) Histologic and microradiologic comparison of block and particulate cancellous bone marrow grafts in reconstructed mandibles being considered for dental implant placement. *J Oral Maxillofac Surg* **54**:15-20.
17. Tadjoeidin E.S., de Lange G.L., Bronckers A.L., Lyaruu D.M. and Burger E.H. (2003) Deproteinized cancellous bovine bone (Bio-Oss) as bone substitute for sinus floor elevation. A retrospective, histomorphometrical study of five cases. *J Clin Periodontol* **30**:261-270.

Research Paper
Bone Substitutes

Proportion of deproteinized bovine bone and autogenous bone affects bone formation in the treatment of calvarial defects in rabbits[☆]

P. Pripatnanont, T. Nuntanaranont, S. Vongvatcharanon

Department of Oral and Maxillofacial Surgery,
Faculty of Dentistry, Prince of Songkla
University, Hatyai, Songkhla, 90112, Thailand

P. Pripatnanont, T. Nuntanaranont, S. Vongvatcharanon: Proportion of deproteinized bovine bone and autogenous bone affects bone formation in the treatment of calvarial defects in rabbits. Int. J. Oral Maxillofac. Surg. 2009; 38: 356–362. © 2009 International Association of Oral and Maxillofacial Surgeons. Published by Elsevier Ltd. All rights reserved.

Abstract. This study assessed new bone formation generated using three different proportions of autogenous bone (AB) and deproteinized bovine bone (DBB). Thirty bicortical skull defects were prepared in 15 rabbits, divided into 3 groups: Group 1, critical size defect (CSD) versus AB as controls; Group 2, DBB versus a composite of AB and DBB using a proportion of 1:1; and Group 3, a composite of AB and DBB using a proportion of 1:2 versus a proportion of 1:4. After 8 weeks, radiographic evaluation was assessed using densitometry and new bone formation by histomorphometry. The mean optical density of the CSD (0.108 ± 0.238) and AB (0.352 ± 0.161) groups differed significantly from the DBB group (1.044 ± 0.093) and the groups using a proportion of 1:1 (0.905 ± 0.078), 1:2 (0.865 ± 0.294) and 1:4 (0.867 ± 0.304). Histomorphometry revealed a higher percentage of new bone in the AB group (30.223 ± 16.722) than in the groups using proportions of 1:2 (22.639 ± 5.659), 1:1 (20.929 ± 6.169), 1:4 (9.621 ± 2.400), DBB (14.441 ± 2.742) and CSD (10.645 ± 8.868), respectively. The 1:2 group had significantly higher bone content than the 1:4 group. The proportions of 1:1 and 1:2 resulted in greater bone formation than the proportion of 1:4, DBB and CSD.

Keywords: autogenous; bovine hydroxyapatite; composite graft; deproteinized bovine bone; graft.

Accepted for publication 9 February 2009
Available online 10 March 2009

Various grafts have been used for the treatment of craniofacial and maxillofacial deformities and defects. The ideal bone graft should be osteoinductive to stimulate osteogenesis and osteoconduc-

tion and provide a scaffold for establishing optimal conditions for in-growth of blood vessels and cells with osteogenic potential and not induce immunological rejection. These requirements are most adequately

[☆] Presented at the 7th Asian Congress on Oral & Maxillofacial Surgery, November 5–9 2006, Hong Kong, China.

fulfilled by autogenous bone grafts, but donor site morbidity and limited volume indicate a need to develop substitute materials for autogenous bone. Deproteinized bovine bone (DBB) is one bone substitute that has a structure similar to human bone and has properties of osteoconduction and biocompatibility⁹. DBB has been used successfully to fill bone defects, particularly in maxillary sinus floor grafting to facilitate dental implants, but it has a slow resorption rate¹², so complete bone formation is slow. A combination of autogenous bone and DBB in appropriate proportions would be an effective choice for bone grafting.

A composite of autogenous bone and bone substitute¹ is widely used clinically because it combines the osteogenic property of autogenous bone and the osteoconductive property of DBB. It contains osteogenic cells and provides a scaffold and internal pores for bone cells to grow and remineralize to new bone². The relative proportions of autogenous bone and bone substitute vary. Several studies preferred a composite of autogenous bone and DBB in a 1:4 proportion, mixed with fibrin glue for sinus grafting. This proportion was not significantly different from autogenous bone or DBB alone in terms of bone healing and osseointegration⁴⁻⁶. Boyne used particulate marrow and cancellous bone mixed with Bio-Oss® (Geistlich pharma AG, Switzerland) in a 1:1 proportion for the treatment of atrophic maxilla and achieved a good result with less bone resorption². Other studies have used proportions of 1:1, 1:2 and 1:4 and achieved good clinical results^{2,6,7}. A systematic review recommended a proportion of 1:2⁸. No published report has compared each proportion directly in clinical studies and animal tests for effective new bone formation^{4,7,14}.

This study assessed the quality and quantity of new bone formation using three different proportions (1:1, 1:2 and 1:4) of autogenous bone and DBB in rabbit calvarial defects.

Materials and methods

Animals

This study was performed in accordance with the regulations and with the approval of the Animal Experiment Ethics Committee of Prince of Songkla University. Fifteen male New Zealand white rabbits aged 5–7 months each weighing 3–4 kg were used for the study. The animals were divided into 3 groups: Group 1 was a control group comprising a critical size defect (CSD)




Fig. 1. SEM photographs of DBB granules showing the pore structure, size 200–500 μm (original magnification, $\times 400$).

versus autogenous bone chips; Group 2 used DBB alone versus a composite of autogenous bone and DBB in a proportion of 1:1; and Group 3 used a composite of autogenous bone and DBB in a proportion of 1:2 versus a proportion of 1:4. The animals were kept in single cages and fed a standard dried diet and water ad libitum.

Material

DBB derived from heat treatment at 1200 °C with grain sizes of 0.25–1 mm was obtained from the Metal and Material Technology Center, Thailand. Previous study showed it was osteoconductive. It has a porous, well-interconnected pore structure and pore size is 200–500 μm ¹⁰ (Fig. 1).

Surgical Procedure

Anesthesia was induced using ketamine 25 mg/kg and diazepam 5 mg/kg intramus-

cularly 30 min before surgery. Thiopental 5 mg/kg was administered intravenously and then titrated at the rate of 2 mg/kg every 15 min (with a maximum dose of no more than 30 mg/kg) until unconsciousness was achieved.

The surgical field was disinfected with povidone-iodine 10%. A mid-sagittal incision was made after local infiltration of 2% lidocaine hydrochloride with 1:100,000 epinephrine 1.8 ml. Subperiosteal dissection was carried out, and 2 bicortical bone defects of 10x10 mm were prepared with a small round bur and a fissure bur using a micro motor (Fig. 2). A sterilized aluminum template was used as a guide to ensure the same sized defect in each animal. A 1 mm deep circular mark was made with a small round bur and filled with preheated gutta percha for later identification of the defect edges on the histological sections. In the control group, autogenous bone from the removed calvarium was minced with a bone morselizer (Salvin Dental Specialties

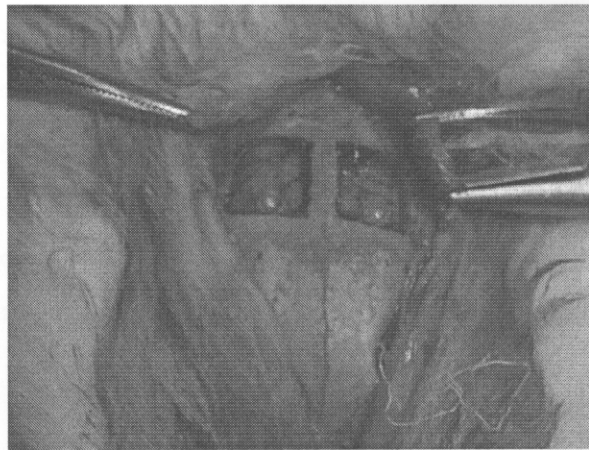


Fig. 2. Defect 10 \times 10 mm at a rabbit's calvarium.

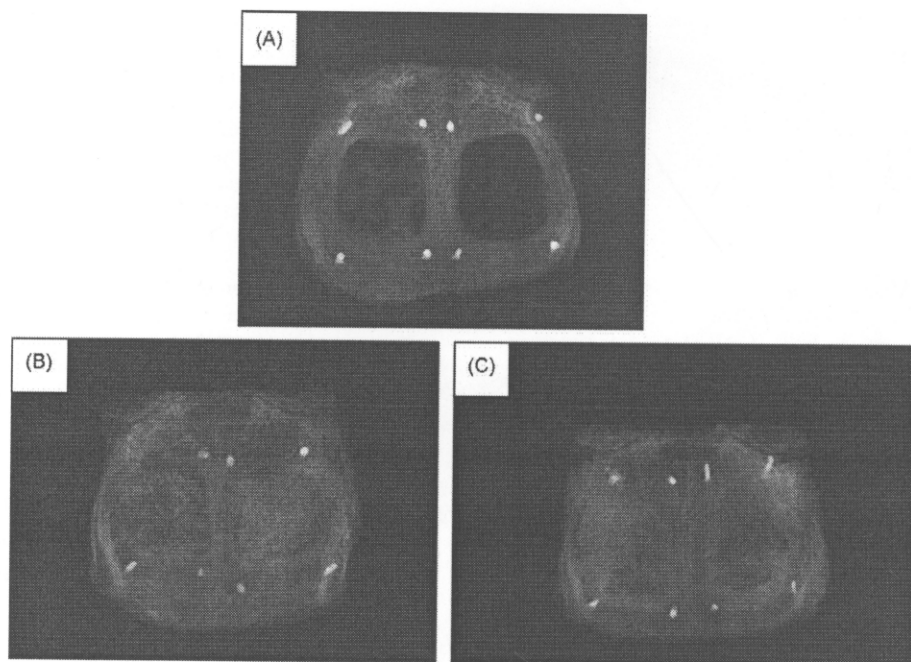


Fig. 3. Photograph of the occlusal films of the rabbits' calvarium. (A) An autogenous at the left side and critical size defect at the right side. (B) A composite graft of autogenous bone and DBB at 1:1 ratio at the left side and DBB alone at the right side. (C) A composite graft of autogenous bone and DBB at 1:4 ratio at the left side and a composite graft of autogenous bone and DBB at 1:2 ratio at the right side.

Inc, Charlotte, NC, USA) and inserted in one side of the defect. The bone morselizer has a 10 mm knurled titanium surface with 1.5 mm serrations, used for crushing bone into small homogeneous pieces to fill each defect. The contralateral side was left empty as a control¹³. In the experimental groups, DBB was soaked with normal saline and mixed with minced autogenous bone from the removed calvarium in different proportions (autogenous:DBB at proportions by weight of 1:1, 1:2 and 1:4 to achieve a total weight of 0.24 mg) and inserted into the defects. The periosteum, muscle and skin were sutured. After 8 weeks, the animals were killed with an overdose (1.2–1.3 ml) of pentobarbital sodium 200 mg/ml administered intravenously. The calvarium was then removed in one piece, fixed in 10% formalin and submitted to radiographic and microscopic analysis for histomorphometric analysis.

Radiograph

To obtain radiographic images of the specimens, the radiographs were exposed with 40 cm dff, 10 mA, 50 kvp for 0.42 s (GX 1000; Gendex Model, Milwaukee, WI, USA). An aluminum step wedge was used for calibration. The images were scanned into the computer with Bio-Rad's

Densitometer GS-700 (Bio-Rad, Hercules, CA, USA), and the mean optical density was calculated and analyzed using Image Pro Plus 5.0 (Media Cybernetics; Silver Spring, MD, USA).

Histology processing

Following radiography, the calvarial specimens were decalcified in formic acid, trimmed, and cut transversally into upper, middle and lower parts and embedded in paraffin. 5 μ m serial sections were cut from each part and stained with hematox-

ilin and eosin. All slides were examined descriptively before histomorphometric analysis.

Histomorphometric analysis

The middle parts of the sections used for histomorphometric analysis were the same as those used for examining histology. They were analyzed by the same examiner using an image analysis system that measured the percentage of newly deposited bone. The system consists of an infinity corrected light micro-

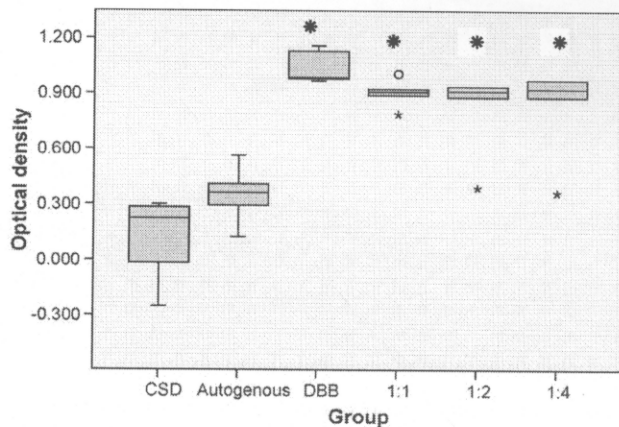


Fig. 4. Mean optical density of rabbit's calvarium specimens. (*) Significant different from the autogenous group and the CSD at $p < 0.05$.

scope (Axiostar; Carl Zeiss, Göttingen, Germany), with objective achromatic 5X and eyepiece 10X, a high resolution digital camera (Axiocam mRC model; Carl Zeiss) with adapter 0.63X to fit the field of view, an image-capture device (Axioversion; Carl Zeiss), and a computer-based image processor for histomorphometry (Image Pro Plus 5.0; Media Cybernetics, MD, USA).

Images of newly formed bone were identified by a given color in each image. These were digitized and transferred to the computer for image processing and analysis of the quantity fraction of the total area of the defect using the formula:

% New bone

$$= \frac{\text{Area of new bone in the defect}}{\text{Total area of the defect}} \times 100$$

Data analysis

Data analysis was conducted using SPSS 14.0 (SPSS Inc, Chicago, IL, USA). Data were tested for normality and one-way analysis of variance and multiple comparison using Tukey HSD test or Dunnett T3 ($p < 0.05$) were carried out to compare the differences between the mean optical densities and the percentage of newly formed bone in the groups.

Results

Radiographic features

In Group 1, CSD, the homogenous radiolucent area consisted almost entirely of bony defect (Fig. 3A). For autogenous bone chips, a radiopaque mass of bone chips of different sizes and density were observed in the defect. A homogeneous radiopaque area around the edge of the defect, with similar density to normal bone, had appeared (Fig. 3A).

In the experimental groups, a well-delineated radiopaque area of bone defect was observed. The bone defects were filled with the distinct radiopaque granules of DBB. The defect treated with DBB alone was more radiopaque than those treated with proportions of 1:1, 1:2 and 1:4, which had similar densities (Fig. 3B, C).

Detailed computer-assisted analysis of the radiographic films is shown in Fig. 4, but no difference between the DBB granules and new bone formation could be discerned. The mean optical density of the CSD (0.108 ± 0.238) and autogenous bone chips (0.352 ± 0.161) was found to be

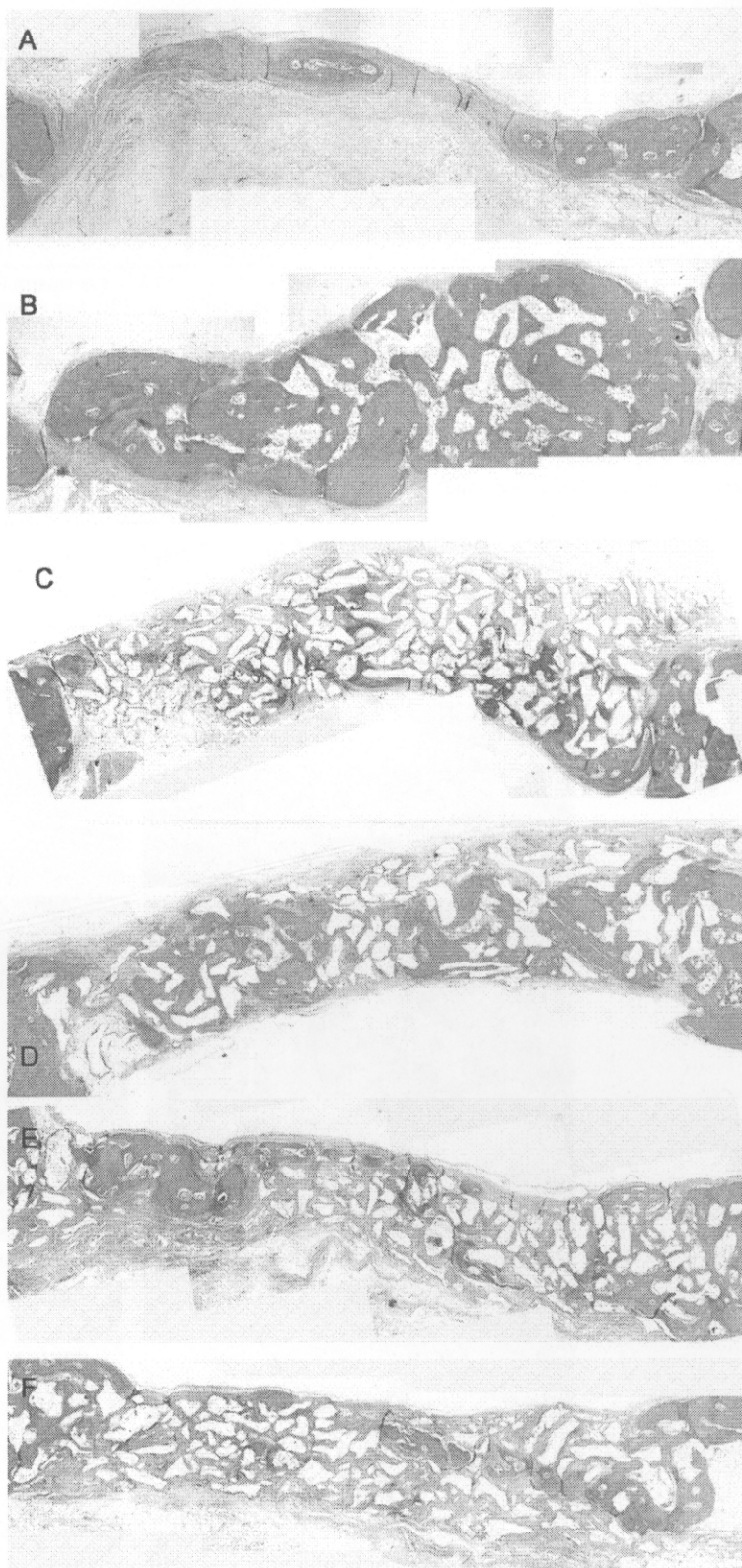


Fig. 5. Micrograph of each specimen (Hematoxylin and Eosin, original magnification x5) (A) A critical size defect (B) An autogenous bone chip (C) DBB alone (D) A composite graft of autogenous bone and DBB at 1:1 ratio (E) A composite graft of autogenous bone and DBB at 1:2 ratio (F) A composite graft of autogenous bone to DBB at 1:4 ratio.

Table 1. The radiographic optical density and the percentage of newly formed bone assessed by histomorphometry are presented (mean \pm standard deviation).

Study group	Optical density (mean \pm SD)	Newly formed bone (%) (mean \pm SD)
CSD	0.108 \pm 0.238	10.645 \pm 8.868
Autogenous	0.352 \pm 0.161	30.223 \pm 16.722
DBB	1.044 \pm 0.093*	14.441 \pm 2.742
Auto:DBB 1:1	0.905 \pm 0.078*	20.929 \pm 6.169
Auto:DBB 1:2	0.865 \pm 0.294*	22.639 \pm 5.659 [†]
Auto:DBB 1:4	0.690 \pm 0.304*	9.621 \pm 2.400

* Significant difference from the autogenous and CSD groups at $p < 0.05$.

[†] Significant difference from the composite of autogenous and DBB at 1:4 ratio group at $p < 0.05$.

significantly lower than that of DBB alone (1.044 \pm 0.093) and the proportion of 1:1 (0.905 \pm 0.078), 1:2 (0.865 \pm 0.294) and 1:4 (0.867 \pm 0.304) (ANOVA, $F = 14.870$;

$df = 5, 24$; $p = 0.000$) (Table 1). The differences between the mean optical densities of each experimental group were not statistically significant.

Histology

For CSD, the defect was filled with a narrow band of loose connective tissue and a little newly formed bone projecting from the defect edge. The contour of the defect appeared collapsed (Figs. 5A, 6A). For autogenous bone chips, the defect was filled with autogenous bone chips and newly formed bone, which combined well with each other and bridged the defect with a full contour (Figs. 5B, 6B).

The defect of the DBB specimen was filled with particles and newly formed bone projected from the defect edge, extending centripetally and combining well with the particles. A little new bone was found in the central part of the defect. The particles and new bone

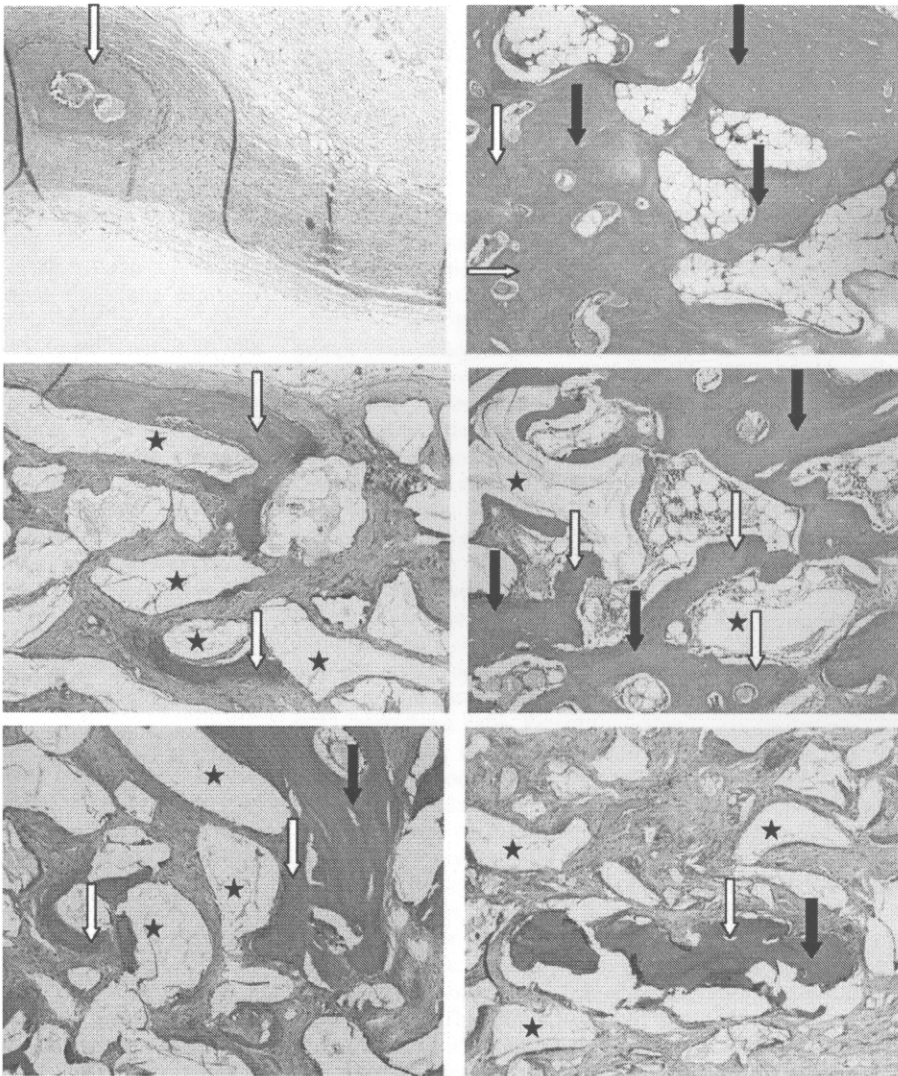


Fig. 6. (A) A critical size defect (B) An auto genous bone chip (C) DBB alone (D) A compos ite graft of autogenous bone and DBB at 1:1 ratio (E) A composite graft of autogenous bone and DBB at 1:2 ratio (F) A composite graft of autogenous bone to DBB at 1:4 ratio. White arrows indicate new bone, black arrows indicate bone chips, black stars indicate DBB particles. (Hematoxylin and Eosin, original magnification $\times 10$).

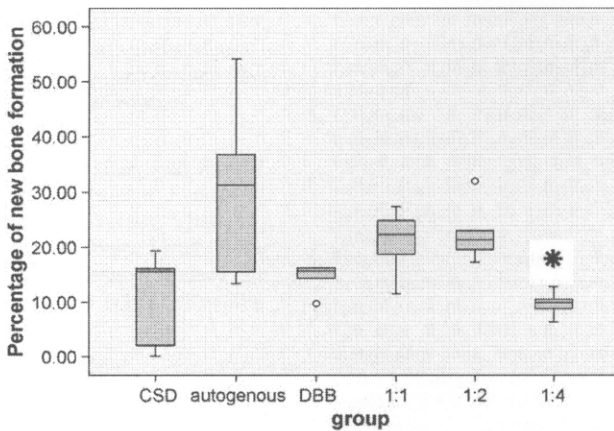


Fig. 7. Percentage of new bone formation from histomorphometry analysis. (*) Significant difference from the group using composite of autogenous and DBB at the proportion of 1:2 at $p < 0.05$.

bridged the defect with a full contour (Figs. 5C, 6C).

For proportion 1:1, the defect was filled with complete bone bridging along the defect, generating newly formed bone throughout the defect. New bone combined well with the autogenous bone chips and filled the defect with a full contour (Figs. 5D, 6D).

For proportion 1:2, the defect presented newly formed bone projecting from the bone edge. At the bone margin, newly formed bone combined well with the DBB particles and autogenous bone chips. Some new bone formation was found in the central part of the defect. The grafting material filled the defect with a normal contour (Figs. 5E, 6E).

For proportion 1:4, the defect presented little newly formed bone projecting from the bone edge with a modest degree of combination with the DBB particles. In the central part, less bone formation was observed than in the other experimental groups. The grafting material filled the defect with a normal contour (Figs. 5F, 6F).

Histomorphometry

Histomorphometric analysis demonstrated that the bone defect implanted with autogenous bone chips (30.223 ± 16.722) presented more bone formation than the other groups but was not statistically significant. Composite grafts in the proportions 1:1 (20.929 ± 6.169) and 1:2 (22.639 ± 5.659) presented larger quantities of bone tissue compared with DBB alone (14.441 ± 2.742) and the CSD group (10.645 ± 8.868); the results were not statistically significant. The composite graft in the proportion 1:2 (22.639 ± 5.659) differed with

statistical significance ($p < 0.05$) from the proportion 1:4 (9.621 ± 2.400) (Dunnett T3, MD = 13.018; $p = 0.039$) (Fig. 7, Table 1).

Discussion

This study compared the percentages of new bone formation generated by three different proportions of autogenous bone and DBB using histomorphometry. The extent of new bone formation for all groups in this study was less than the bone formation observed in other studies⁶, which may be because the amounts of bone packed into the rabbits' calvarial defects were calculated by weight unlike other studies in which they were calculated by volume. The calculation of proportions by weight results in a lower volume of fresh autogenous bone than dry DBB because it contains blood and is soaked with normal saline solution during the operation, resulting in a greater total weight that does not represent the net weight of the autogenous bone and contains fewer bone cells. Proportion calculated by weight is a more accurate and consistent method of measurement than proportion calculated by volume.

Rabbits were used in this experiment because their physiological bone healing is similar to that of humans, but the rate of healing is 3 times higher than in humans. Other reasons for using rabbits were their availability, the accessibility of the calvarial defects, ease of manipulation and ethical acceptance. The 8 week time span was chosen because it represents the remodeling phase of bone healing in the rabbit, which is sufficient to prove the property of CSD that no complete bone healing occurred and to ensure the capability of

bone formation in the experimental group. Physiologically, 8 weeks in the rabbit can be compared with 6–8 months in humans. This is relevant to clinical practice because it is the time span for bone grafting, particularly in sinus grafting¹⁵.

In the past, Bio-Oss[®], which is a deproteinized cancellous bovine bone treated using a chemical agent, was widely used as a bone substitute because its structure is similar to that of human bone. Many studies claimed its properties of osteoconduction and biocompatibility were beneficial to the human body^{2,3,9,11}.

This study used DBB, heat treated at 1200 °C, and the histology results reveal the osteoconductive property and biocompatibility of this material.

Several studies have used proportions of 1:1 and 1:2 for clinical use, but they each presented only one proportion and evaluated the clinical results or the histology of bone implant contact but did not carry out a histomorphometric analysis^{2,7,8}. HALLMAN et al. used the proportion of 1:4 compared with autogenous bone alone and deproteinized cancellous bovine bone alone^{6,14} and proposed that a 1:4 proportion could enhance bone formation of a quality similar to autogenous bone.

The present results have proved that proportions of 1:1 and 1:2 enhance bone formation compared with the proportion of 1:4 and DBB alone. The level of new bone formation with proportions of 1:1 and 1:2 was less than that observed in the autogenous group, but they have advantages in terms of the slow resorption rate of the grafted area, bridging of the defect with a full contour, and lower morbidity of the donor site.

This study demonstrated the difference between the 1:2 and the 1:4 proportion in histomorphometry, which confirms that the 1:1 and 1:2 proportions are better than 1:4 in terms of new bone formation. The differences between other groups could not be demonstrated because of wide variations in the data, particularly in the autogenous group and the CSD group. In the CSD group, the defect was not filled so there was only a narrow band of fibrous tissue. As the total area in the CSD group was collapsed, and therefore smaller than that of the other filled defect groups, the estimated percentage of new bone overestimated the actual amount of new bone. No significant differences in the proportion of new bone in the tested and the control groups were found, but the ability of the composite graft to promote new bone formation and fill the defect could be demonstrated qualitatively. Proportions of 1:1 and 1:2 seem reliable compared

with the other proportions in terms of new bone formation. Composite grafts of autogenous bone and DBB can bridge the defect and give a normal contour.

Acknowledgments. This study was funded by the Thailand Government Fund and Prince of Songkla University Thailand. The authors thank Professor Henk Tide-man and Dr Alan Geater, Prince of Songkla University, for his proofreading and advice.

References

1. AL RUHAIMI KA. Bone graft substitutes: a comparative qualitative histologic review of current osteoconductive grafting materials. *Int J Oral Maxillofac Implants* 2001; **16**: 105–114.
2. BOYNE PJ. Osseous reconstruction of the maxilla and the mandible. *Chicago Quintessence* 1997: 25–74.
3. FUKUTA K, HAR-SHAI Y, COLLARES MV, LICHTEN JB, JACKSON IT. Comparison of inorganic bovine bone mineral particles with porous hydroxyapatite granules and cranial bone dust in the reconstruction of full-thickness skull defect. *J Craniofac Surg* 1992; **3**: 25–29.
4. HALLMAN M, CEDERLUND A, LINDSKOG S, LUNDGREN S, SENNERBY L. A clinical histologic study of bovine hydroxyapatite in combination with autogenous bone and fibrin glue for maxillary sinus floor augmentation. Results after 6 to 8 months of healing. *Clin Oral Implants Res* 2001; **12**: 135–143.
5. HALLMAN M, NORDIN T. Sinus floor augmentation with bovine hydroxyapatite mixed with fibrin glue and later placement of nonsubmerged implants: a retrospective study in 50 patients. *Int J Oral Maxillofac Implants* 2004; **19**: 222–227.
6. HALLMAN M, SENNERBY L, LUNDGREN S. A clinical and histologic evaluation of implant integration in the posterior maxilla after sinus floor augmentation with autogenous bone, bovine hydroxyapatite, or a 20:80 mixture. *Int J Oral Maxillofac Implants* 2002; **17**: 635–643.
7. MAIORANA C, SANTORO F, RABAGLIATI M, SALINA S. Evaluation of the use of iliac cancellous bone and anorganic bovine bone in the reconstruction of the atrophic maxilla with titanium mesh: a clinical and histologic investigation. *Int J Oral Maxillofac Implants* 2001; **16**: 427–432.
8. MERKX MA, MALTHA JC, STOELINGA PJ. Assessment of the value of anorganic bone additives in sinus floor augmentation: a review of clinical reports. *Int J Oral Maxillofac Surg* 2003; **32**: 1–6.
9. PIATTELLI M, FAVERO GA, SCARANO A, ORSINI G, PIATTELLI A. Bone reactions to anorganic bovine bone (Bio-Oss) used in sinus augmentation procedures: a histologic long-term report of 20 cases in humans. *Int J Oral Maxillofac Implants* 1999; **14**: 835–840.
10. PRIPATNANONT P, NUNTANARANONT T, VONGVATCHARANON S, LIMLERTMONGKOL S. Osteoconductive effects of three heat-treated hydroxyapatites in rabbit calvarial defects. *J Oral Maxillofac Surg* 2007; **65**: 2418–2424.
11. SCHLEGEL AK, DONATH K. BIO-OSS—a resorbable bone substitute? *J Long Term Eff Med Implants* 1998; **8**: 201–209.
12. SCHLEGEL KA, FICHTNER G, SCHULTZE-MOSGAU S, WILTFANG J. Histologic findings in sinus augmentation with autogenous bone chips versus a bovine bone substitute. *Int J Oral Maxillofac Implants* 2003; **18**: 53–58.
13. SCHMITZ JP, HOLLINGER JO. The critical size defect as an experimental model for craniomandibulofacial nonunions. *Clin Orthop Relat Res* 1986; **205**: 299–308.
14. TADJOEDIN ES, DE LANGE GL, BRONCKERS AL, LYARUU DM, BURGER EH. Deproteinized cancellous bovine bone (Bio-Oss) as bone substitute for sinus floor elevation. A retrospective, histomorphometrical study of five cases. *J Clin Periodontol* 2003; **30**: 261–270.
15. WATANABE K, NIIMI A, UEDA M. Autogenous bone graft in the rabbit maxillary sinus. *Oral Surg Oral Med Oral Pathol Oral Radiol Endod* 1999; **88**: 26–32.

Address: *Prisana Pripatnanont*
 Tel: +66 74 429876
 Fax: +66 74 429876
 E-mail: *prisana.p@psu.ac.th*

Research Paper
Bone Substitutes

Proportion of deproteinized bovine bone and autogenous bone affects bone formation in the treatment of calvarial defects in rabbits[☆]

P. Pripatnanont, T. Nuntanaranont, S. Vongvatcharanon
Department of Oral and Maxillofacial Surgery,
Faculty of Dentistry, Prince of Songkla
University, Hatyai, Songkhla, 90112, Thailand

P. Pripatnanont, T. Nuntanaranont, S. Vongvatcharanon: Proportion of deproteinized bovine bone and autogenous bone affects bone formation in the treatment of calvarial defects in rabbits. Int. J. Oral Maxillofac. Surg. 2009; 38: 356–362. © 2009 International Association of Oral and Maxillofacial Surgeons. Published by Elsevier Ltd. All rights reserved.

Abstract. This study assessed new bone formation generated using three different proportions of autogenous bone (AB) and deproteinized bovine bone (DBB). Thirty bicortical skull defects were prepared in 15 rabbits, divided into 3 groups: Group 1, critical size defect (CSD) versus AB as controls; Group 2, DBB versus a composite of AB and DBB using a proportion of 1:1; and Group 3, a composite of AB and DBB using a proportion of 1:2 versus a proportion of 1:4. After 8 weeks, radiographic evaluation was assessed using densitometry and new bone formation by histomorphometry. The mean optical density of the CSD (0.108 ± 0.238) and AB (0.352 ± 0.161) groups differed significantly from the DBB group (1.044 ± 0.093) and the groups using a proportion of 1:1 (0.905 ± 0.078), 1:2 (0.865 ± 0.294) and 1:4 (0.867 ± 0.304). Histomorphometry revealed a higher percentage of new bone in the AB group (30.223 ± 16.722) than in the groups using proportions of 1:2 (22.639 ± 5.659), 1:1 (20.929 ± 6.169), 1:4 (9.621 ± 2.400), DBB (14.441 ± 2.742) and CSD (10.645 ± 8.868), respectively. The 1:2 group had significantly higher bone content than the 1:4 group. The proportions of 1:1 and 1:2 resulted in greater bone formation than the proportion of 1:4, DBB and CSD.

Keywords: autogenous; bovine hydroxyapatite; composite graft; deproteinized bovine bone; graft.

Accepted for publication 9 February 2009
Available online 10 March 2009

[☆] Presented at the 7th Asian Congress on Oral & Maxillofacial Surgery, November 5–9 2006, Hong Kong, China.

Various grafts have been used for the treatment of craniofacial and maxillofacial deformities and defects. The ideal bone graft should be osteoinductive to stimulate osteogenesis and osteoconduc-

tion and provide a scaffold for establishing optimal conditions for in-growth of blood vessels and cells with osteogenic potential and not induce immunological rejection. These requirements are most adequately

fulfilled by autogenous bone grafts, but donor site morbidity and limited volume indicate a need to develop substitute materials for autogenous bone. Deproteinized bovine bone (DBB) is one bone substitute that has a structure similar to human bone and has properties of osteoconduction and biocompatibility⁹. DBB has been used successfully to fill bone defects, particularly in maxillary sinus floor grafting to facilitate dental implants, but it has a slow resorption rate¹², so complete bone formation is slow. A combination of autogenous bone and DBB in appropriate proportions would be an effective choice for bone grafting.

A composite of autogenous bone and bone substitute¹ is widely used clinically because it combines the osteogenic property of autogenous bone and the osteoconductive property of DBB. It contains osteogenic cells and provides a scaffold and internal pores for bone cells to grow and remineralize to new bone². The relative proportions of autogenous bone and bone substitute vary. Several studies preferred a composite of autogenous bone and DBB in a 1:4 proportion, mixed with fibrin glue for sinus grafting. This proportion was not significantly different from autogenous bone or DBB alone in terms of bone healing and osseointegration⁴⁻⁶. Boyne used particulate marrow and cancellous bone mixed with Bio-Oss® (Geistlich pharma AG, Switzerland) in a 1:1 proportion for the treatment of atrophic maxilla and achieved a good result with less bone resorption². Other studies have used proportions of 1:1, 1:2 and 1:4 and achieved good clinical results^{2,6,7}. A systematic review recommended a proportion of 1:2⁸. No published report has compared each proportion directly in clinical studies and animal tests for effective new bone formation^{4,7,14}.

This study assessed the quality and quantity of new bone formation using three different proportions (1:1, 1:2 and 1:4) of autogenous bone and DBB in rabbit calvarial defects.

Materials and methods

Animals

This study was performed in accordance with the regulations and with the approval of the Animal Experiment Ethics Committee of Prince of Songkla University. Fifteen male New Zealand white rabbits aged 5-7 months each weighing 3-4 kg were used for the study. The animals were divided into 3 groups: Group 1 was a control group comprising a critical size defect (CSD)




Fig. 1. SEM photographs of DBB granules showing the pore structure, size 200-500 μm (original magnification, $\times 400$).

versus autogenous bone chips; Group 2 used DBB alone versus a composite of autogenous bone and DBB in a proportion of 1:1; and Group 3 used a composite of autogenous bone and DBB in a proportion of 1:2 versus a proportion of 1:4. The animals were kept in single cages and fed a standard dried diet and water ad libitum.

Material

DBB derived from heat treatment at 1200 °C with grain sizes of 0.25-1 mm was obtained from the Metal and Material Technology Center, Thailand. Previous study showed it was osteoconductive. It has a porous, well-interconnected pore structure and pore size is 200-500 μm ¹⁰ (Fig. 1).

Surgical Procedure

Anesthesia was induced using ketamine 25 mg/kg and diazepam 5 mg/kg intramus-

cularly 30 min before surgery. Thiopental 5 mg/kg was administered intravenously and then titrated at the rate of 2 mg/kg every 15 min (with a maximum dose of no more than 30 mg/kg) until unconsciousness was achieved.

The surgical field was disinfected with povidone-iodine 10%. A mid-sagittal incision was made after local infiltration of 2% lidocaine hydrochloride with 1:100,000 epinephrine 1.8 ml. Subperiosteal dissection was carried out, and 2 bicortical bone defects of 10x10 mm were prepared with a small round bur and a fissure bur using a micro motor (Fig. 2). A sterilized aluminum template was used as a guide to ensure the same sized defect in each animal. A 1 mm deep circular mark was made with a small round bur and filled with preheated gutta percha for later identification of the defect edges on the histological sections. In the control group, autogenous bone from the removed calvarium was minced with a bone morselizer (Salvin Dental Specialties

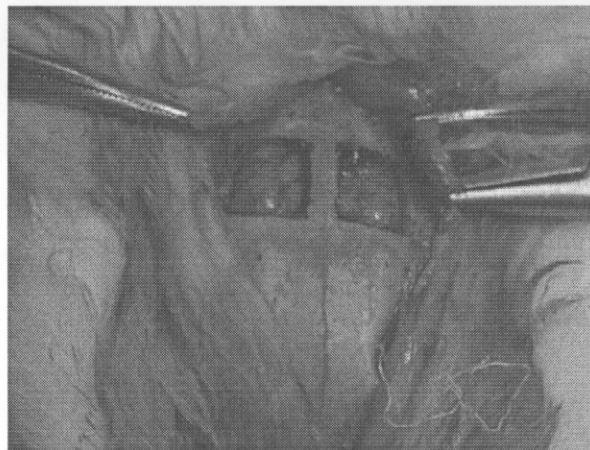


Fig. 2. Defect 10 x 10 mm at a rabbit's calvarium.

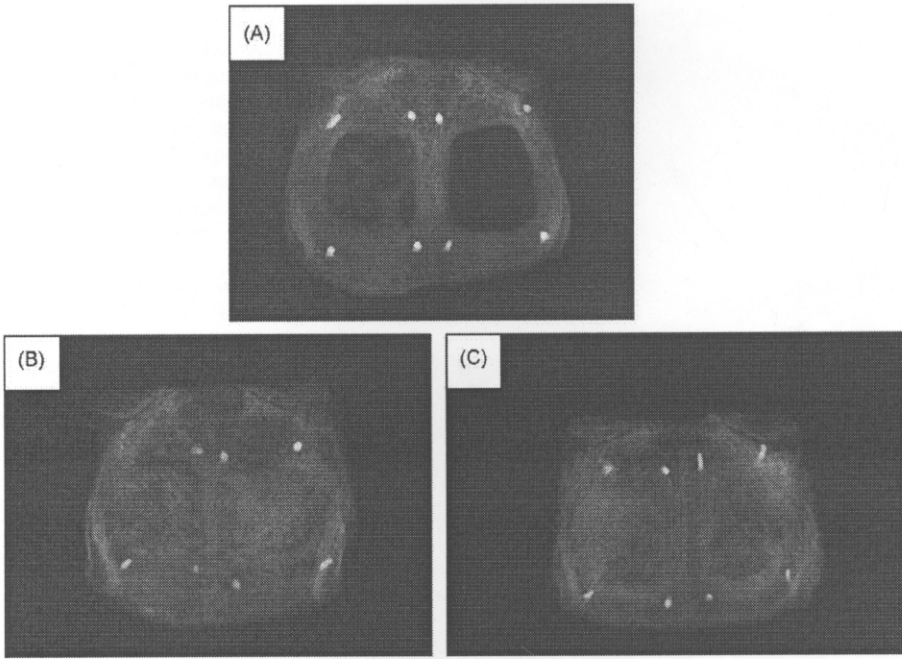


Fig. 3. Photograph of the occlusal films of the rabbits' calvarium. (A) An autogenous at the left side and critical size defect at the right side. (B) A composite graft of autogenous bone and DBB at 1:1 ratio at the left side and DBB alone at the right side. (C) A composite graft of autogenous bone and DBB at 1:4 ratio at the left side and a composite graft of autogenous bone and DBB at 1:2 ratio at the right side.

Inc, Charlotte, NC, USA) and inserted in one side of the defect. The bone morselizer has a 10 mm knurled titanium surface with 1.5 mm serrations, used for crushing bone into small homogeneous pieces to fill each defect. The contralateral side was left empty as a control¹³. In the experimental groups, DBB was soaked with normal saline and mixed with minced autogenous bone from the removed calvarium in different proportions (autogenous:DBB at proportions by weight of 1:1, 1:2 and 1:4 to achieve a total weight of 0.24 mg) and inserted into the defects. The periosteum, muscle and skin were sutured. After 8 weeks, the animals were killed with an overdose (1.2–1.3 ml) of pentobarbital sodium 200 mg/ml administered intravenously. The calvarium was then removed in one piece, fixed in 10% formalin and submitted to radiographic and microscopic analysis for histomorphometric analysis.

Radiograph

To obtain radiographic images of the specimens, the radiographs were exposed with 40 cm dff, 10 mA, 50 kvp for 0.42 s (GX 1000; Genex Model, Milwaukee, WI, USA). An aluminum step wedge was used for calibration. The images were scanned into the computer with Bio-Rad's

Densitometer GS-700 (Bio-Rad, Hercules, CA, USA), and the mean optical density was calculated and analyzed using Image Pro Plus 5.0 (Media Cybernetics; Silver Spring, MD, USA).

Histology processing

Following radiography, the calvarial specimens were decalcified in formic acid, trimmed, and cut transversally into upper, middle and lower parts and embedded in paraffin. 5 µm serial sections were cut from each part and stained with hematox-

ilin and eosin. All slides were examined descriptively before histomorphometric analysis.

Histomorphometric analysis

The middle parts of the sections used for histomorphometric analysis were the same as those used for examining histology. They were analyzed by the same examiner using an image analysis system that measured the percentage of newly deposited bone. The system consists of an infinity corrected light micro-

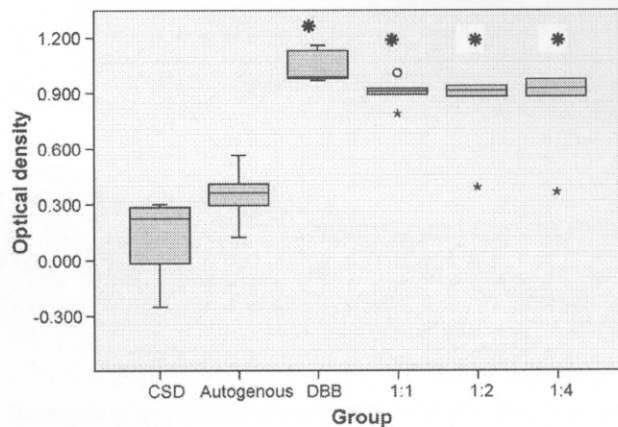


Fig. 4. Mean optical density of rabbit's calvarium specimens. (*) Significant different from the autogenous group and the CSD at $p < 0.05$.

scope (Axiostar; Carl Zeiss, Göttingen, Germany), with objective achromatic 5X and eyepiece 10X, a high resolution digital camera (Axiocam mRC model; Carl Zeiss) with adapter 0.63X to fit the field of view, an image-capture device (Axioverision; Carl Zeiss), and a computer-based image processor for histomorphometry (Image Pro Plus 5.0; Media Cybernetics, MD, USA).

Images of newly formed bone were identified by a given color in each image. These were digitized and transferred to the computer for image processing and analysis of the quantity fraction of the total area of the defect using the formula:

% New bone

$$= \frac{\text{Area of new bone in the defect}}{\text{Total area of the defect}} \times 100$$

Data analysis

Data analysis was conducted using SPSS 14.0 (SPSS Inc, Chicago, IL, USA). Data were tested for normality and one-way analysis of variance and multiple comparison using Tukey HSD test or Dunnett T3 ($p < 0.05$) were carried out to compare the differences between the mean optical densities and the percentage of newly formed bone in the groups.

Results

Radiographic features

In Group 1, CSD, the homogenous radiolucent area consisted almost entirely of bony defect (Fig. 3A). For autogenous bone chips, a radiopaque mass of bone chips of different sizes and density were observed in the defect. A homogeneous radiopaque area around the edge of the defect, with similar density to normal bone, had appeared (Fig. 3A).

In the experimental groups, a well-delineated radiopaque area of bone defect was observed. The bone defects were filled with the distinct radiopaque granules of DBB. The defect treated with DBB alone was more radiopaque than those treated with proportions of 1:1, 1:2 and 1:4, which had similar densities (Fig. 3B, C).

Detailed computer-assisted analysis of the radiographic films is shown in Fig. 4, but no difference between the DBB granules and new bone formation could be discerned. The mean optical density of the CSD (0.108 ± 0.238) and autogenous bone chips (0.352 ± 0.161) was found to be

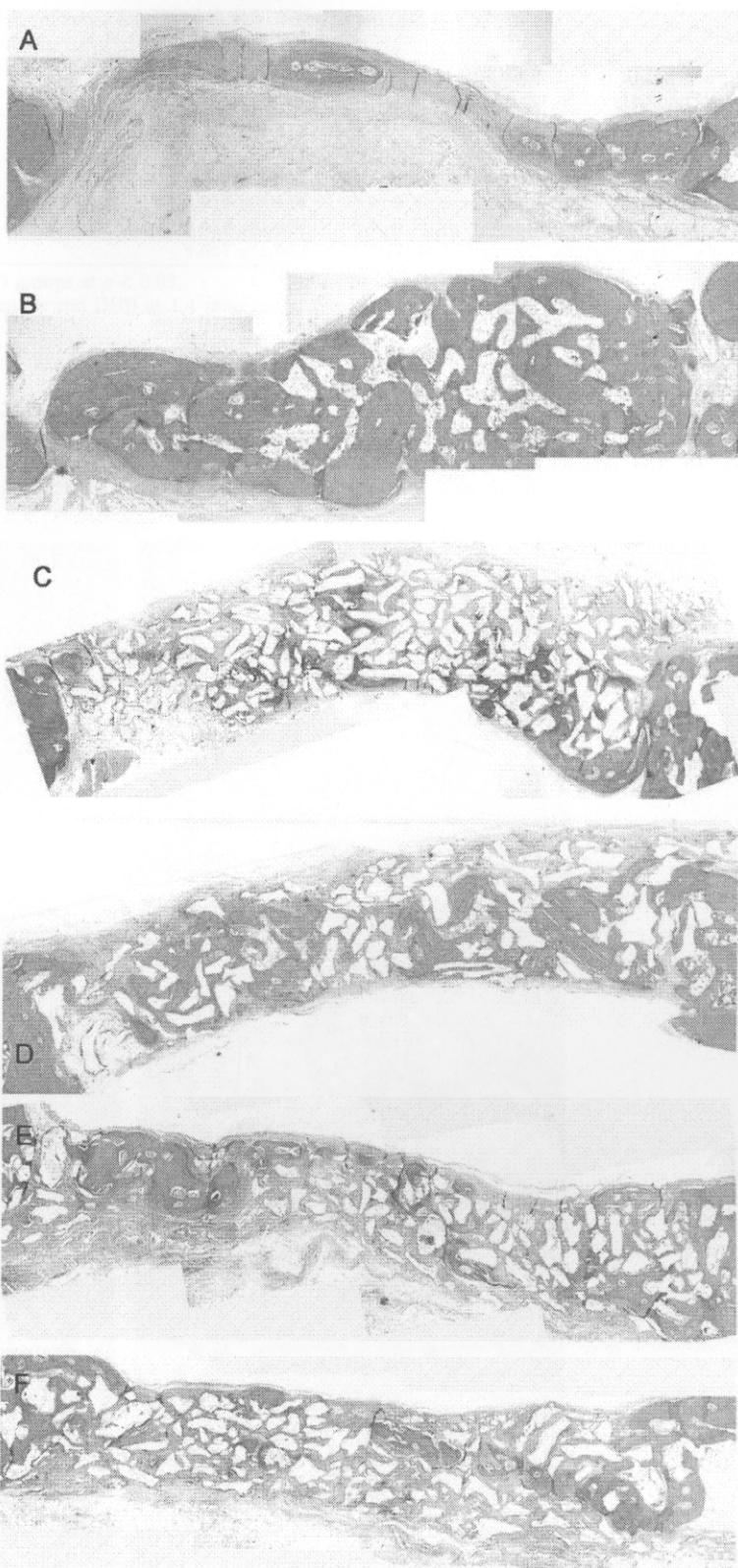


Fig. 5. Micrograph of each specimen (Hematoxylin and Eosin, original magnification x5) (A) A critical size defect (B) An autogenous bone chip (C) DBB alone (D) A composite graft of autogenous bone and DBB at 1:1 ratio (E) A composite graft of autogenous bone and DBB at 1:2 ratio (F) A composite graft of autogenous bone to DBB at 1:4 ratio.

Table 1. The radiographic optical density and the percentage of newly formed bone assessed by histomorphometry are presented (mean \pm standard deviation).

Study group	Optical density (mean \pm SD)	Newly formed bone (%) (mean \pm SD)
CSD	0.108 \pm 0.238	10.645 \pm 8.868
Autogenous	0.352 \pm 0.161	30.223 \pm 16.722
DBB	1.044 \pm 0.093*	14.441 \pm 2.742
Auto:DBB 1:1	0.905 \pm 0.078*	20.929 \pm 6.169
Auto:DBB 1:2	0.865 \pm 0.294*	22.639 \pm 5.659 [†]
Auto:DBB 1:4	0.690 \pm 0.304*	9.621 \pm 2.400

*Significant difference from the autogenous and CSD groups at $p < 0.05$.

[†]Significant difference from the composite of autogenous and DBB at 1:4 ratio group at $p < 0.05$.

significantly lower than that of DBB alone (1.044 \pm 0.093) and the proportion of 1:1 (0.905 \pm 0.078), 1:2 (0.865 \pm 0.294) and 1:4 (0.867 \pm 0.304) (ANOVA, $F = 14.870$;

$df = 5, 24$; $p = 0.000$) (Table 1). The differences between the mean optical densities of each experimental group were not statistically significant.

Histology

For CSD, the defect was filled with a narrow band of loose connective tissue and a little newly formed bone projecting from the defect edge. The contour of the defect appeared collapsed (Figs. 5A, 6A). For autogenous bone chips, the defect was filled with autogenous bone chips and newly formed bone, which combined well with each other and bridged the defect with a full contour (Figs. 5B, 6B).

The defect of the DBB specimen was filled with particles and newly formed bone projected from the defect edge, extending centripetally and combining well with the particles. A little new bone was found in the central part of the defect. The particles and new bone

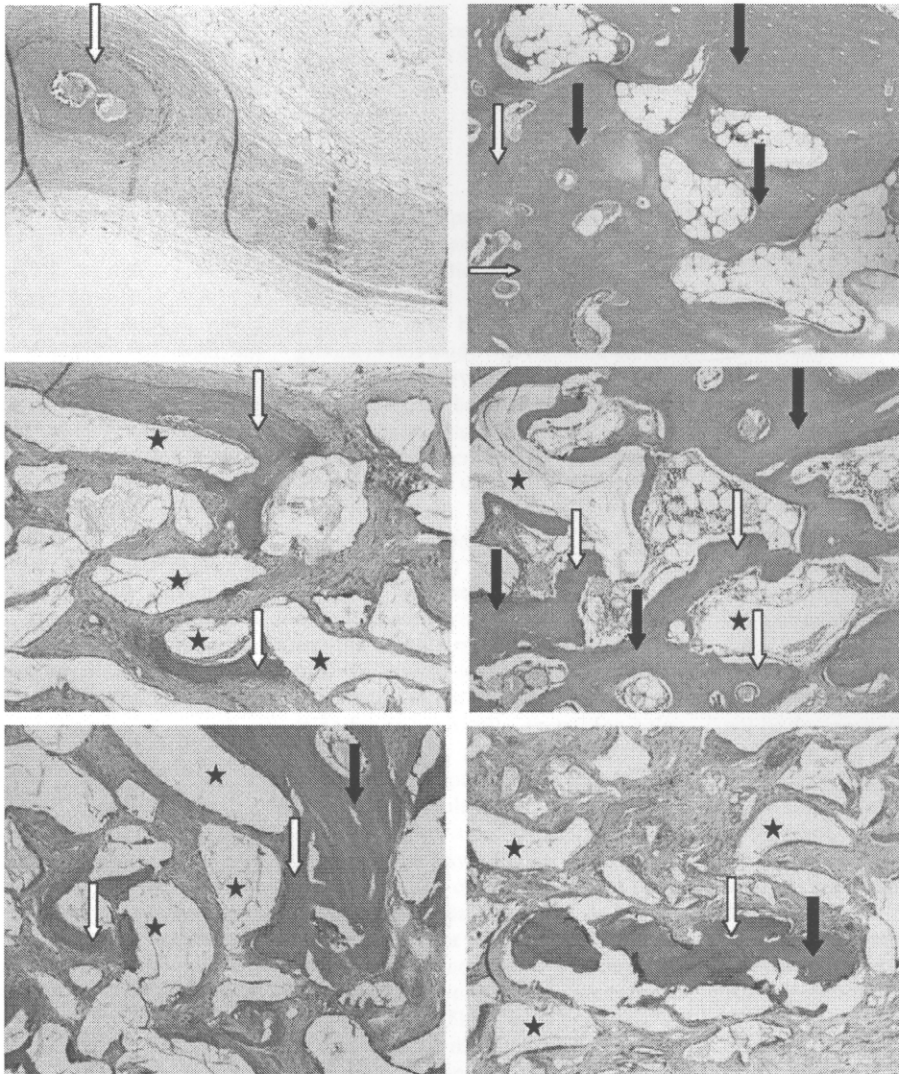


Fig. 6. (A) A critical size defect (B) An auto genous bone chip (C) DBB alone (D) A composite graft of autogenous bone and DBB at 1:1 ratio (E) A composite graft of autogenous bone and DBB at 1:2 ratio (F) A composite graft of autogenous bone to DBB at 1:4 ratio. White arrows indicate new bone, black arrows indicate bone chips, black stars indicate DBB particles. (Hematoxylin and Eosin, original magnification $\times 10$).

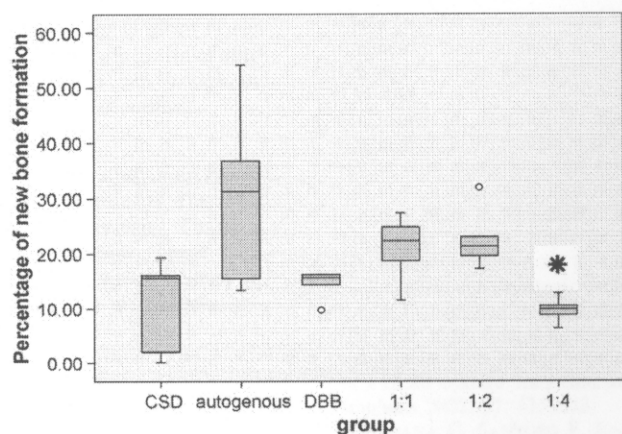


Fig. 7. Percentage of new bone formation from histomorphometry analysis. (*) Significant difference from the group using composite of autogenous and DBB at the proportion of 1:2 at $p < 0.05$.

bridged the defect with a full contour (Figs. 5C, 6C).

For proportion 1:1, the defect was filled with complete bone bridging along the defect, generating newly formed bone throughout the defect. New bone combined well with the autogenous bone chips and filled the defect with a full contour (Figs. 5D, 6D).

For proportion 1:2, the defect presented newly formed bone projecting from the bone edge. At the bone margin, newly formed bone combined well with the DBB particles and autogenous bone chips. Some new bone formation was found in the central part of the defect. The grafting material filled the defect with a normal contour (Figs. 5E, 6E).

For proportion 1:4, the defect presented little newly formed bone projecting from the bone edge with a modest degree of combination with the DBB particles. In the central part, less bone formation was observed than in the other experimental groups. The grafting material filled the defect with a normal contour (Figs. 5F, 6F).

Histomorphometry

Histomorphometric analysis demonstrated that the bone defect implanted with autogenous bone chips (30.223 ± 16.722) presented more bone formation than the other groups but was not statistically significant. Composite grafts in the proportions 1:1 (20.929 ± 6.169) and 1:2 (22.639 ± 5.659) presented larger quantities of bone tissue compared with DBB alone (14.441 ± 2.742) and the CSD group (10.645 ± 8.868); the results were not statistically significant. The composite graft in the proportion 1:2 (22.639 ± 5.659) differed with

statistical significance ($p < 0.05$) from the proportion 1:4 (9.621 ± 2.400) (Dunnett T3, MD = 13.018; $p = 0.039$) (Fig. 7, Table 1).

Discussion

This study compared the percentages of new bone formation generated by three different proportions of autogenous bone and DBB using histomorphometry. The extent of new bone formation for all groups in this study was less than the bone formation observed in other studies⁶, which may be because the amounts of bone packed into the rabbits' calvarial defects were calculated by weight unlike other studies in which they were calculated by volume. The calculation of proportions by weight results in a lower volume of fresh autogenous bone than dry DBB because it contains blood and is soaked with normal saline solution during the operation, resulting in a greater total weight that does not represent the net weight of the autogenous bone and contains fewer bone cells. Proportion calculated by weight is a more accurate and consistent method of measurement than proportion calculated by volume.

Rabbits were used in this experiment because their physiological bone healing is similar to that of humans, but the rate of healing is 3 times higher than in humans. Other reasons for using rabbits were their availability, the accessibility of the calvarial defects, ease of manipulation and ethical acceptance. The 8 week time span was chosen because it represents the remodeling phase of bone healing in the rabbit, which is sufficient to prove the property of CSD that no complete bone healing occurred and to ensure the capability of

bone formation in the experimental group. Physiologically, 8 weeks in the rabbit can be compared with 6–8 months in humans. This is relevant to clinical practice because it is the time span for bone grafting, particularly in sinus grafting¹⁵.

In the past, Bio-Oss[®], which is a deproteinized cancellous bovine bone treated using a chemical agent, was widely used as a bone substitute because its structure is similar to that of human bone. Many studies claimed its properties of osteoconduction and biocompatibility were beneficial to the human body^{2,3,9,11}.

This study used DBB, heat treated at 1200 °C, and the histology results reveal the osteoconductive property and biocompatibility of this material.

Several studies have used proportions of 1:1 and 1:2 for clinical use, but they each presented only one proportion and evaluated the clinical results or the histology of bone implant contact but did not carry out a histomorphometric analysis^{2,7,8}. HALLMAN et al. used the proportion of 1:4 compared with autogenous bone alone and deproteinized cancellous bovine bone alone^{6,14} and proposed that a 1:4 proportion could enhance bone formation of a quality similar to autogenous bone.

The present results have proved that proportions of 1:1 and 1:2 enhance bone formation compared with the proportion of 1:4 and DBB alone. The level of new bone formation with proportions of 1:1 and 1:2 was less than that observed in the autogenous group, but they have advantages in terms of the slow resorption rate of the grafted area, bridging of the defect with a full contour, and lower morbidity of the donor site.

This study demonstrated the difference between the 1:2 and the 1:4 proportion in histomorphometry, which confirms that the 1:1 and 1:2 proportions are better than 1:4 in terms of new bone formation. The differences between other groups could not be demonstrated because of wide variations in the data, particularly in the autogenous group and the CSD group. In the CSD group, the defect was not filled so there was only a narrow band of fibrous tissue. As the total area in the CSD group was collapsed, and therefore smaller than that of the other filled defect groups, the estimated percentage of new bone overestimated the actual amount of new bone. No significant differences in the proportion of new bone in the tested and the control groups were found, but the ability of the composite graft to promote new bone formation and fill the defect could be demonstrated qualitatively. Proportions of 1:1 and 1:2 seem reliable compared

with the other proportions in terms of new bone formation. Composite grafts of autogenous bone and DBB can bridge the defect and give a normal contour.

Acknowledgments. This study was funded by the Thailand Government Fund and Prince of Songkla University Thailand. The authors thank Professor Henk Tide-man and Dr Alan Geater, Prince of Songkla University, for his proofreading and advice.

References

1. AL RUHAIMI KA. Bone graft substitutes: a comparative qualitative histologic review of current osteoconductive grafting materials. *Int J Oral Maxillofac Implants* 2001; **16**: 105–114.
2. BOYNE PJ. Osseous reconstruction of the maxilla and the mandible. Chicago Quintessence 1997: 25–74.
3. FUKUTA K, HAR-SHAI Y, COLLARES MV, LICHTEN JB, JACKSON IT. Comparison of inorganic bovine bone mineral particles with porous hydroxyapatite granules and cranial bone dust in the reconstruction of full-thickness skull defect. *J Craniofac Surg* 1992; **3**: 25–29.
4. HALLMAN M, CEDERLUND A, LINDSKOG S, LUNDGREN S, SENNERBY L. A clinical histologic study of bovine hydroxyapatite in combination with autogenous bone and fibrin glue for maxillary sinus floor augmentation. Results after 6 to 8 months of healing. *Clin Oral Implants Res* 2001; **12**: 135–143.
5. HALLMAN M, NORDIN T. Sinus floor augmentation with bovine hydroxyapatite mixed with fibrin glue and later placement of nonsubmerged implants: a retrospective study in 50 patients. *Int J Oral Maxillofac Implants* 2004; **19**: 222–227.
6. HALLMAN M, SENNERBY L, LUNDGREN S. A clinical and histologic evaluation of implant integration in the posterior maxilla after sinus floor augmentation with autogenous bone, bovine hydroxyapatite, or a 20:80 mixture. *Int J Oral Maxillofac Implants* 2002; **17**: 635–643.
7. MAIORANA C, SANTORO F, RABAGLIATI M, SALINA S. Evaluation of the use of iliac cancellous bone and anorganic bovine bone in the reconstruction of the atrophic maxilla with titanium mesh: a clinical and histologic investigation. *Int J Oral Maxillofac Implants* 2001; **16**: 427–432.
8. MERKX MA, MALTHA JC, STOELINGA PJ. Assessment of the value of anorganic bone additives in sinus floor augmentation: a review of clinical reports. *Int J Oral Maxillofac Surg* 2003; **32**: 1–6.
9. PIATTELLI M, FAVERO GA, SCARANO A, ORSINI G, PIATTELLI A. Bone reactions to anorganic bovine bone (Bio-Oss) used in sinus augmentation procedures: a histologic long-term report of 20 cases in humans. *Int J Oral Maxillofac Implants* 1999; **14**: 835–840.
10. PRIPATNANONT P, NUNTANARANONT T, VONGVATCHARANON S, LIMLERTMONGKOL S. Osteoconductive effects of three heat-treated hydroxyapatites in rabbit calvarial defects. *J Oral Maxillofac Surg* 2007; **65**: 2418–2424.
11. SCHLEGEL AK, DONATH K. BIO-OSS—a resorbable bone substitute? *J Long Term Eff Med Implants* 1998; **8**: 201–209.
12. SCHLEGEL KA, FICHTNER G, SCHULTZ-MOSGAU S, WILTFANG J. Histologic findings in sinus augmentation with autogenous bone chips versus a bovine bone substitute. *Int J Oral Maxillofac Implants* 2003; **18**: 53–58.
13. SCHMITZ JP, HOLLINGER JO. The critical size defect as an experimental model for craniomandibulofacial nonunions. *Clin Orthop Relat Res* 1986; **205**: 299–308.
14. TADJOEDIN ES, DE LANGE GL, BRONCKERS AL, LYARUU DM, BURGER EH. Deproteinized cancellous bovine bone (Bio-Oss) as bone substitute for sinus floor elevation. A retrospective, histomorphometrical study of five cases. *J Clin Periodontol* 2003; **30**: 261–270.
15. WATANABE K, NIIMI A, UEDA M. Autogenous bone graft in the rabbit maxillary sinus. *Oral Surg Oral Med Oral Pathol Oral Radiol Endod* 1999; **88**: 26–32.

Address: *Prisana Pripatnanont*
 Tel: +66 74 429876
 Fax: +66 74 429876
 E-mail: *prisana.p@psu.ac.th*